

Effects of the Neurotrophin Brain-Derived Neurotrophic Factor in an Experimental Model of Retinal Detachment

Geoffrey P. Lewis,¹ Kenneth A. Linberg,¹ Scott F. Geller,^{1,2} Christopher J. Guérin,^{1,3} and Steven K. Fisher^{1,2}

PURPOSE. To examine the effects of brain-derived neurotrophic factor (BDNF) in an animal model of retinal detachment.

METHODS. Cat retinas were detached from the retinal pigment epithelium for either 7 or 28 days. Animals received either an intravitreal injection of BDNF (100 μ g) or phosphate-buffered saline (PBS), the vehicle for BDNF. Retinas were evaluated using morphology and immunocytochemistry. The width of the outer segment zone was measured, and the retinas were evaluated for changes in protein expression by labeling with antibodies to rod opsin, phosducin, synaptophysin, calbindin D, and glial fibrillary acidic protein (GFAP). The effect of BDNF on both proliferation and apoptotic cell death was examined.

RESULTS. Although there was variability in the treated retinas, most of the animals receiving BDNF had well-organized outer segments that were longer than those in vehicle-treated controls. Immunocytochemistry revealed that treated retinas had consistently less opsin redistribution to the plasma membrane, less phosducin upregulation, and fewer calbindin D-labeled horizontal cell processes. BDNF did not reduce overall cell death in the detachments or death of photoreceptors by apoptosis. However, it significantly reduced the proliferative response of Müller cells and the extent of upregulation of GFAP.

CONCLUSIONS. The results suggest that BDNF may aid in the recovery of the retina after reattachment by maintaining the surviving photoreceptor cells, by reducing the gliotic effects in Müller cells, and perhaps by promoting outer segment regeneration. (*Invest Ophthalmol Vis Sci.* 1999;40:1530-1544)

Several biologic molecules have been shown to rescue rodent photoreceptors from various genetic degenerations and the damaging effects of light¹⁻⁴ with brain-derived neurotrophic factor (BDNF) proving to be one of the most potent and one with no apparent undesirable effects. In this study it was our goal to test its ability to rescue photoreceptors from the degeneration induced by retinal detachment.

Retinal detachment is a common cause of human visual impairment. For many years, outer segment degeneration was considered the primary effect of detachment and their imperfect regeneration the most likely cause of continued visual deficits after successful reattachment.⁵ Using a feline model of detachment, we have shown that detachment leads to a number of other cellular events that could all effect the degree of

visual recovery: photoreceptor cell death,^{6,7} Müller cell proliferation and hypertrophy,^{6,8,9,10} and the remodeling of photoreceptor synaptic terminals.¹¹ Rod outer segment degeneration is always characterized by a changed expression or intracellular redistribution of molecules such as rhodopsin and peripherin/rds.^{12,13} Müller cell hypertrophy is associated with an increased expression of the intermediate filament proteins (e.g., glial fibrillary acidic protein, GFAP), and a decrease in the expression of others.^{14,15} The structural remodeling of surviving photoreceptors is correlated with their loss of specific cytoskeletal¹⁶ and synaptic vesicle proteins and a concomitant outgrowth of neurites from second-order neurons.¹¹ Although these responses are predictable events after retinal detachment in this model system, they do not occur with the same precision in timing and magnitude of similar events in the genetic or light damage models. For example, photoreceptor cell death always occurs, but it can be variable between animals and often patchy along the length of detached retina.^{5,17}

These experiments were originally designed to determine whether BDNF would protect photoreceptors from degeneration and cell death in this model. The study was expanded to include other cellular events in photoreceptors, second-order neurons, and Müller cells. After detachment, BDNF may not prevent outer segment degeneration or reduce cell death, but instead, it appears to maintain the surviving photoreceptors, including their synaptic endings; reduce the gliotic responses of Müller cells; and perhaps stimulate outer segment regeneration.

From the ¹Neuroscience Research Institute and ²Molecular, Cellular and Developmental Biology, University of California, Santa Barbara.

Supported by Research Grant EY00888 from the U.S. Public Health Service, Washington, DC, and a grant from Amgen, Inc., Thousand Oaks, California, and Regeneron Pharmaceuticals, Inc., Tarrytown, New York, partners.

Submitted for publication October 16, 1998; revised February 4, 1999; accepted February 24, 1999.

Proprietary interest category: C5.

³Present address: Neurotoxicology Group, MRC Toxicology Unit, University of Leicester, Leicester, LE1 9HN UK.

Reprint requests: Geoffrey P. Lewis, Neuroscience Research Institute, University of California, Santa Barbara, CA 93106.

TABLE 1. Experimental Design for BDNF Photoreceptor Rescue Experiments

Day	-14	-2	0*	3	7	14	28
Experimental groups:							
A (n = 5)	Lens removed		RD	BDNF injection†	Sacrifice		
B (n = 10)	Lens removed	BDNF injection†	RD	BDNF injection†	Sacrifice		
C (n = 5)	Lens removed		RD	BDNF injection†		BDNF injection†	Sacrifice
D (n = 10)	Lens removed	BDNF injection†	RD	BDNF injection†		BDNF injection†	Sacrifice
Control groups:							
E (n = 3)	Lens removed	PBS injection	RD	PBS injection	Sacrifice		
F (n = 5)	Lens removed	PBS injection	RD	PBS injection		PBS injection	Sacrifice
G (n = 4)	Lens removed		RD				Sacrifice
H (n = 5)	Lens removed	BDNF injection†	VIT‡	BDNF injection†		BDNF injection†	Sacrifice
I (n = 2)		BDNF injection†		BDNF injection†		BDNF injection†	Sacrifice

* Refers to time of retinal detachment.

† Human recombinant BDNF, 100 µg.

‡ Vitrectomy only.

MATERIALS AND METHODS

Retinal Detachments and Intraocular Injections

Table 1 summarizes the experimental design of the photoreceptor rescue portion of the study. Adult cat retinas were detached as described previously.¹⁷ Briefly, the lens and vitreous were removed using a fragmatome and ocutome inserted at the region of the pars plana. A glass micropipette (100-µm tip diameter) attached to a micromanipulator was then used to infuse a solution of 0.25% sodium hyaluronate (Healon; Pharmacia, Piscataway, NJ) in balanced salt solution (Alcon, Fort Worth, TX) between the neural retina and retinal pigment epithelium (RPE). When approximately 50% to 75% of the retina was detached, the pipette was removed and the scleral incision closed with 8-0 nylon suture. This procedure resulted in only a small hole in the retina; no retinal tears were observed. The injections of BDNF or PBS (the vehicle for BDNF) were given according to either a postdetachment or a predetachment schedule. The 7-day animals in the former group (Table 1, group A) received an intraocular injection of BDNF only (100 µg in 50 µl PBS) on day 3 (n = 5), whereas the 28-day group (Table 1, group C) received injections on days 3 and 14 (n = 5). The 7-day predetachment group (Table 1, group B) received BDNF on days -2 and 3 (n = 10), and the 28-day animals in this group (Table 1, group D) received injections on days -2, 3, and 14 (n = 10). Controls for the effects of BDNF consisted of eyes with 7-day retinal detachments that received injections of PBS on days -2 and 3 (n = 3; Table 1, group E); eyes with 28-day retinal detachments that received injections of PBS on days -2, 3, and 14 (n = 7; Table 1, group F); eyes with retinal detachments but no injections (n = 4; Table 1, group G); eyes that had the lens and vitreous removed without retinal detachment but had postoperative injections of BDNF 12 (equivalent to -2 on the detachment schedule), 17 (equivalent to +3), and 28 (equivalent to +14) days later (n = 5; Table 1, group H); and completely normal eyes that received three injections of BDNF spaced according to this same schedule over a 30-day period (n = 2, Table 1, group I). All injections were performed at the level of the pars plana using a 30-gauge needle. After the injection, the needle was held in place for approximately a minute. As the needle was slowly withdrawn, the sclera was compressed with forceps to help minimize leakage from the injection site. All procedures involving animals adhered to the ARVO Statement for the Use of Animals in Ophthalmic and Vision Research and University of

California, Santa Barbara guidelines for the use of animals in research.

Tissue Preparation

The eyes were dissected into eighths (Fig. 1). Region 2 from the superior nasal retina was fixed and stored in 4% paraformaldehyde in sodium cacodylate buffer (0.1 N; pH 7.4) for

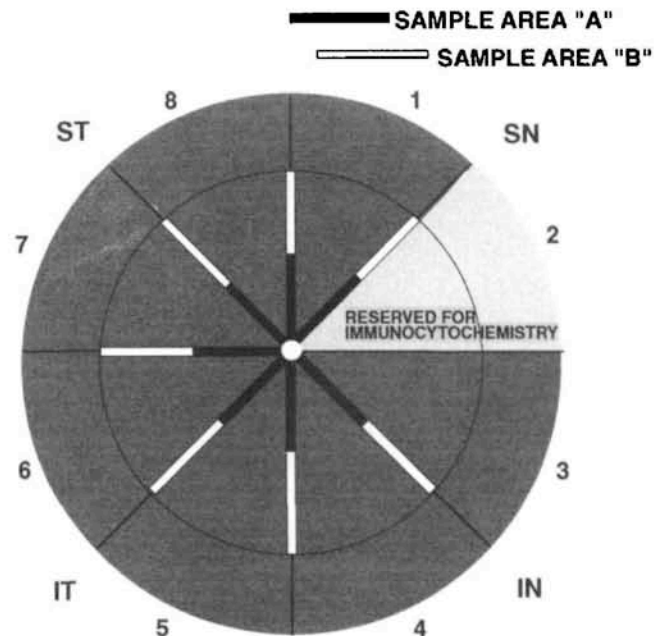
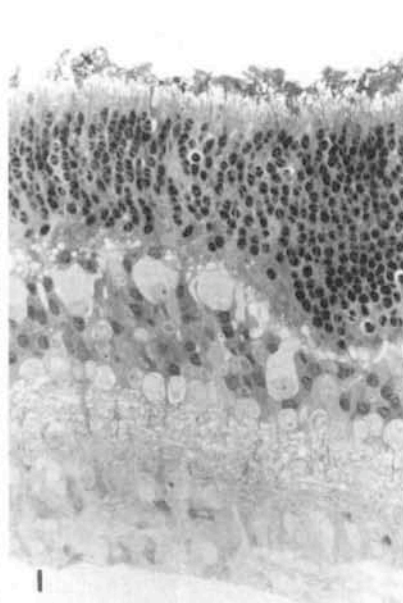
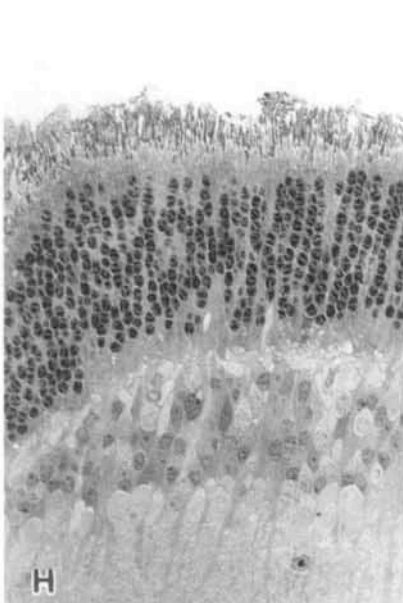
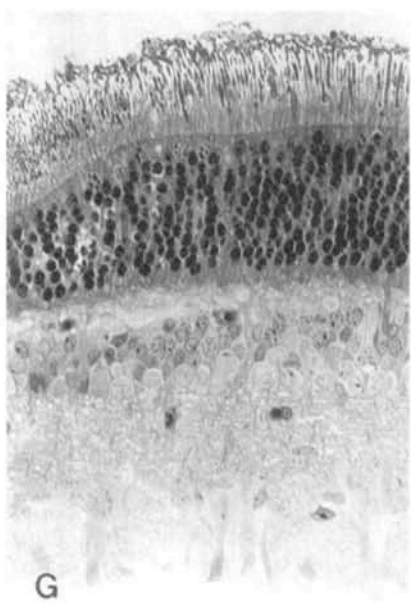
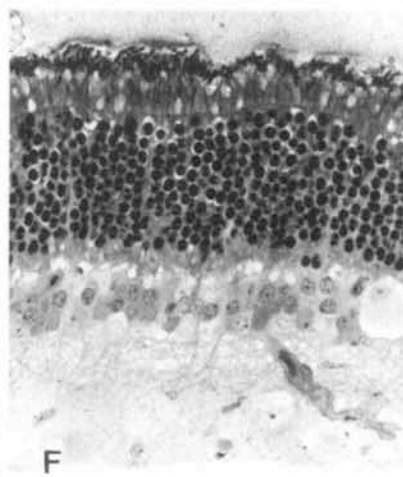
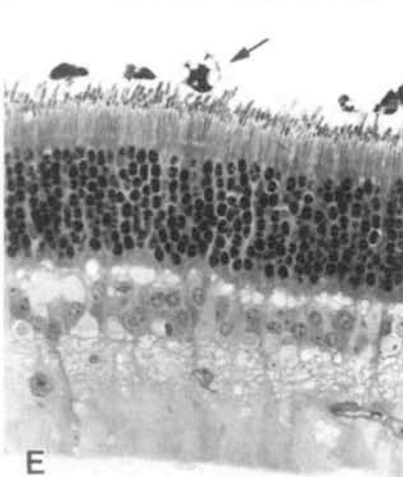
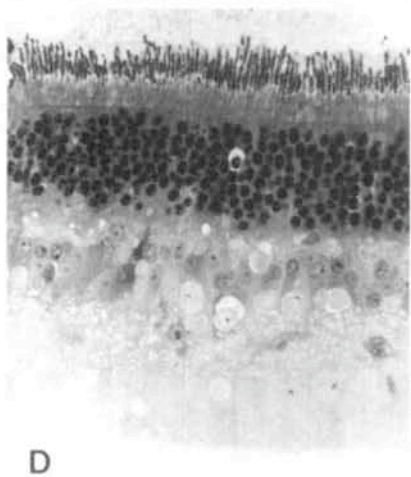
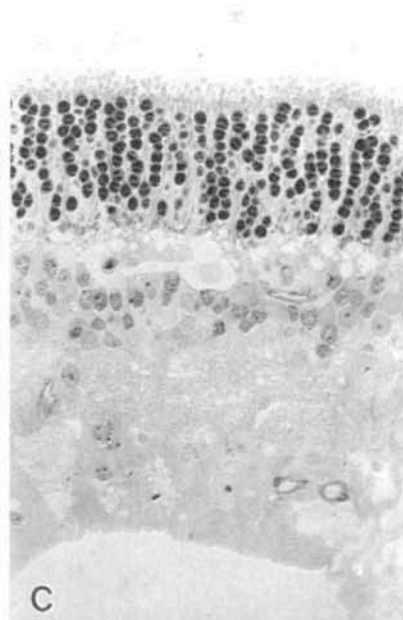
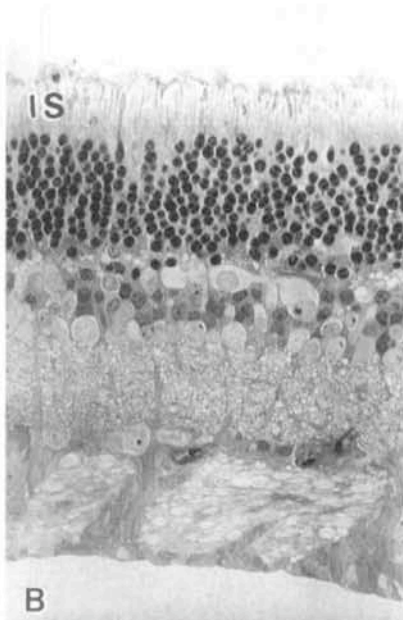
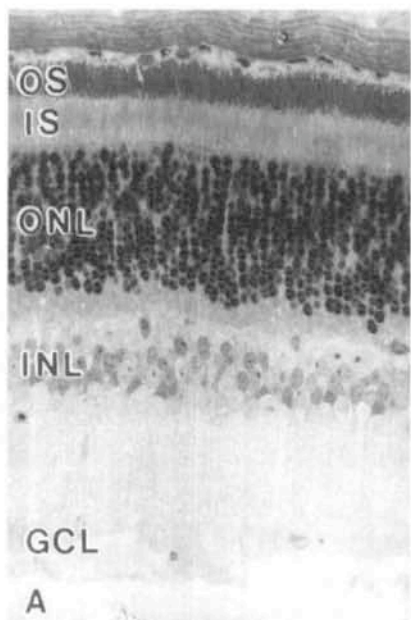


FIGURE 1. A diagram showing how the eyecups were divided in the rescue experiments. The fundus was divided into approximately eight equal wedge-shaped pieces centered on the optic nerve head. Segment 2 was fixed in paraformaldehyde and reserved for immunocytochemistry. The other pieces were fixed for light and electron microscopy and embedded in resin. The sampling areas for the morphologic study of the retinas are indicated by the areas marked "A" (black bars) and "B" (white bars) from each of these seven wedges. Each of these areas was approximately 3 mm to 4 mm in length, but the length of detached retina within each of these blocks varied. (The diagram reflects sampling methods and is not drawn to scale.) SN, superior nasal; ST, superior temporal; IN, inferior nasal; IT, inferior temporal.



immunocytochemistry. The remaining seven regions were immersion fixed in 1% glutaraldehyde and 1% paraformaldehyde in sodium phosphate buffer (0.086 M; pH 7.3) overnight at 4°C. The tissue was then fixed in phosphate-buffered osmium tetroxide (2%) for 1 hour and embedded in Spurr's resin. The 7 regions were divided in half producing 1 central (area A) and 1 peripheral location (area B) from each, for a total of 14 retinal locations. Each location was sectioned at 1 μm , counterstained with toluidine blue, and examined by light microscopy and, in some cases, by electron microscopy.

The immunohistochemical procedures using 100- μm thick Vibratome (Technical Products International, Poly-science, Warrington, PA) sections and laser scanning confocal microscopy were published previously.^{10,11,18} Anti-rhodopsin (gift from Robert Molday, University of Vancouver) was used at a 1:50 dilution, anti-phosducin (gift from Toshimichi Shinohara, Harvard University) at 1:400, anti-calbindin D (Sigma, St. Louis, MO) at 1:1000, anti-synaptophysin (Dako, Carpinteria, CA) at 1:100, and anti-GFAP (Dako) at 1:500. After 1° antibody incubation, the sections were rinsed and incubated in donkey anti-mouse or -rabbit IgG conjugated to the fluorochrome Cy3 (Jackson ImmunoResearch, West Grove, PA) overnight at 4°C on a rotator. Sections were then rinsed again, mounted in 5% *n*-propyl gallate in glycerol, and viewed on a laser scanning confocal microscope (model 1024; Bio-Rad, Hercules, CA).

Quantifying the Effects

Photoreceptor Morphology. Two methods were used to evaluate the effects of BDNF on photoreceptor morphology. In both, slides were coded so that the treatment was not known to the observers (SKF, GPL). One method involved measuring the width of the outer segment zone. From each eye 42 measurements were taken (3 representative areas on a section from each of the 14 regions) and combined to obtain an average outer segment length for each animal. The second method involved the same two observers independently rating the status of the photoreceptors on a scale of 0 to 5, with 0 indicating no outer segments and 5 indicating normal appearance. A single number was assigned by consensus. Both methods were used on the same sections.

Photoreceptor Cell Counts. We sampled the number of nuclei in the outer nuclear layer (ONL) in two blocks (Fig. 1, sample areas A and B) for the superior nasal retina in each animal. The length of the section was measured and the midpoint of the section centered in the microscope field. All the photoreceptor nuclei within a length of 750 μm centered on the midpoint were counted. The identity of the tissue was masked to the observer.

Immunocytochemistry. We quantitated the immunocytochemical results by comparing BDNF-treated and PBS-treated 28-day detachments with normal retina and untreated 28-day detachments. The extent of deviation from normal was rated on a scale of 0 to 3, with 0 indicating equivalence to the pattern in normal retina and 3 representing the expected response in a 28-day untreated retinal detachment. The sections were processed together, and gain and contrast settings were kept constant while viewing on the confocal microscope. At least five animals were used for each antibody, and the ratings were combined to obtain an average.

Proliferation and Apoptosis. We could not use tissue from the described experiments to determine whether BDNF affects cell proliferation or cell death by apoptosis, because the peak of both responses occurs before 7 days.^{7,8} Therefore, a new set of detachments was made in the right eyes of five cats. Three of these had 100 μg BDNF in PBS injected into the vitreous cavity within 10 minutes after the detachment surgery, and two of them received a comparable volume of PBS. All animals were sacrificed 3 days later. Eyes were fixed for immunocytochemistry as above and the retina embedded in wax (Paraplast X-tra; Fisher Scientific, Pittsburgh, PA).

Anti-Ki-67 and TdT-dUTP Terminal Nick-End Labeling. Four-micrometer-thick sections were dried on microscope slides, dewaxed in xylene, rehydrated in graded ethanol, and labeled with the antibody to Ki-67 (1:50; Immunotech, Westbrook, ME) using an automated histostainer (TechMate 1000; BioTek Solutions, Santa Barbara, CA) to detect proliferating cells.⁹ The labeled cells were counted and the section length measured to determine the number of dividing cells per millimeter of retina. Wax sections were prepared as above and stained by the TdT-dUTP terminal nick-end labeling (TUNEL) method.⁷ The number of labeled (apoptotic) cells per millimeter of retina was counted for each sample. In both studies, cell types were classified according to their stratification and morphology.

RESULTS

Morphology

The morphology of retinas detached for 7 or 28 days and receiving PBS, was consistent with results in earlier studies.^{5,6,19} Outer and inner segments showed signs of severe degeneration at both 7 and 28 days (compare Figs. 2A, 2B, 2C). As expected, photoreceptor cell loss was patchy but obvious at both times (Figs. 2B, 2C). We consistently found other expected changes: disruption of the photoreceptor synaptic ter-

FIGURE 2. Light micrographs selected to show the range of responses of detached retina to BDNF. Resin-embedded tissue, 1- μm sections, toluidine blue stain. (A) Normal cat retina. This example is taken from one of the eyes given three intraocular injections of BDNF to show that these retinas had a completely normal morphology. (B) PBS-treated retina detached for 7 days. Note the nearly complete outer segment degeneration. (C) PBS-treated retina detached for 28 days. Note the complete absence of outer segments and greatly shortened inner segments. There are numerous spaces within the ONL indicative of photoreceptor cell loss. (D, E, F, G, H, I). Examples of the range of positive responses to BDNF in retinas detached for 7 (D, E, F) or 28 (G, H, I) days. In (D) the outer segments are nearly normal in length and well organized. In (E) outer segments vary in length, and there are numerous macrophages in the subretinal space (*arrow*). In (F) there is a broad zone of outer segment material, but it is not particularly well organized. In (G) the outer segments are longer than in normal cat retina, measuring up to 36 μm in many areas. Note that the tips of the outer segments are distorted. (H) Essentially normal-length outer segments were present in a 28-day detachment, whereas the outer segments (I) were shorter than normal and poorly organized. OS, outer segment layer; IS, inner segment layer; ONL, outer nuclear layer; INL, inner nuclear layer; GCL, ganglion cell layer. Magnification, $\times 300$.

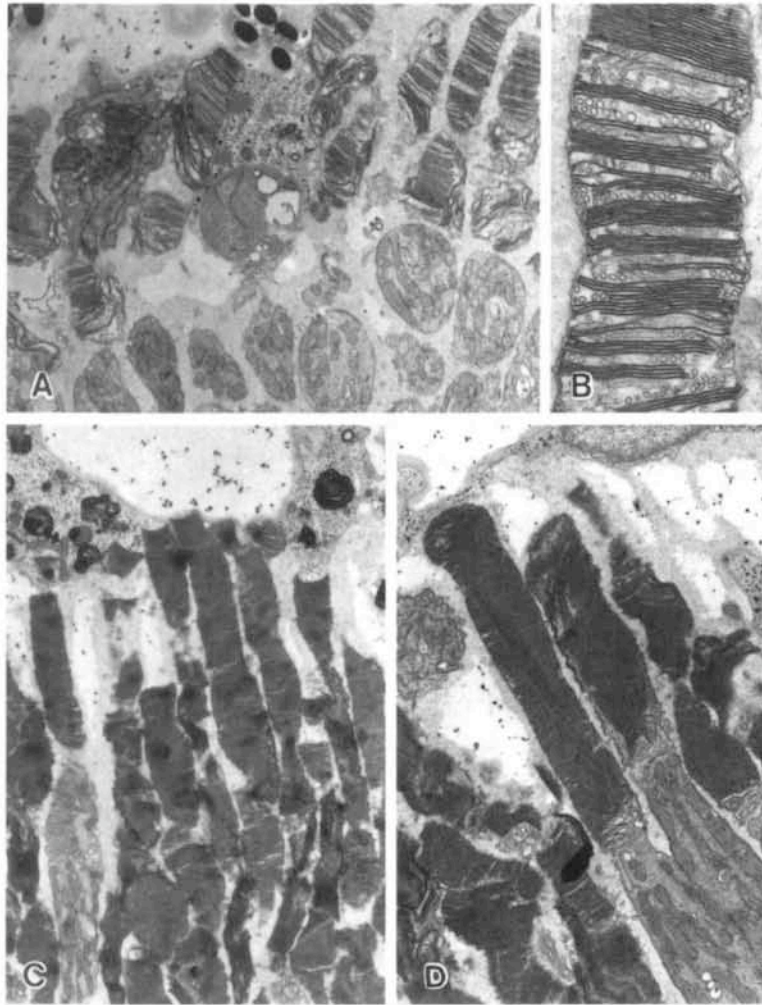


FIGURE 3. Electron micrographs of photoreceptor outer segments from retinas detached for 7 days and either PBS- (A, B) or BDNF- (C, D) treated (study groups E and B; Table 1). In the PBS-treated retinas, those photoreceptor cells that have recognizable outer segments at 7 days of detachment by light microscopy usually appeared highly abnormal when examined by electron microscopy, as shown. (C, D) Exceptionally well-organized outer segments in retinas detached for 7 days and treated with BDNF. Note the presence of many phagosomes in the macrophage adjoining the apical tips of the outer segments in (C). Magnification, (A) $\times 4,070$; (B) $\times 15,600$; (C) $\times 3,700$; (D) $\times 4,900$.

minals, Müller cell nuclei displacement to the outer retina or subretinal space, the obvious hypertrophy of Müller cell processes both within the retina and the subretinal space, and the occasional occurrence of RPE cells and, rarely, macrophages (Fig. 2E, arrow) in the expanded subretinal space.

Figures 2D, 2E, 2F, 2G, 2H, and 2I illustrate what were considered to be positive morphologic responses in the retinas treated with BDNF—that is, retinal morphology unlike that found in the PBS-injected or untreated control detachments. The full range of responses in the BDNF-treated retinas would also include results as shown in Figures 2B and 2C, because in some animals, and even in some regions of retinas showing a positive response, there were also negative responses—that is, the degeneration typical of detachment of this duration. Outer segment morphology in the BDNF-treated retinas showing a positive response ranged from almost normal in appearance (Figs. 2D, 2E, 2H) to only slightly better than in the PBS-treated detachments (Fig. 2I). In several instances, the outer segments

were actually longer than in attached, control retinas (Fig. 2G), although in these cases the tips of the outer segments were always disrupted. In some eyes a broad zone of outer segment membrane was not organized into typical outer segments (Fig. 2F). When present, macrophages often contained packets of outer segment discs (e.g., Fig. 3C). Although the morphology left us with the impression that photoreceptor synaptic terminals were less disrupted and Müller cells less reactive in the BDNF-treated retinas, these responses were best and most reliably documented by the immunocytochemistry described later. There were no other obvious morphologic differences between PBS- and BDNF-treated retinas.

In some areas of the PBS-injected eyes there were truncated outer segments, but at the ultrastructural level these always appeared as vesiculated and disorganized fragments of outer segments (Figs. 3A, 3B, 4A). By contrast, the BDNF-injected eyes had consistently both longer and better-organized outer segments (Figs. 3C, 3D, 4B), with many of them showing

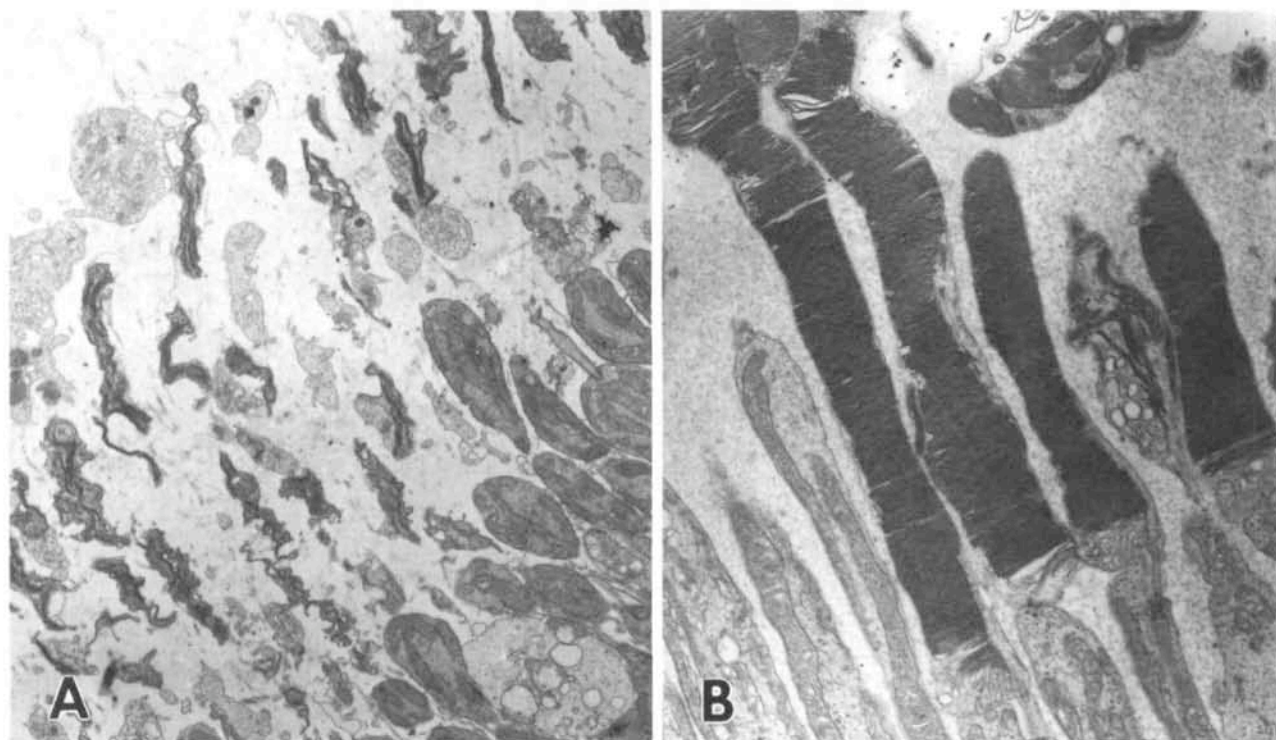


FIGURE 4. Electron micrographs of photoreceptor outer segments from retinas detached for 28 days. Outer segments are usually completely degenerated by 28 days of detachment. The example shown in (A) from a PBS-treated eye in study group F is typical. Only disorganized fragments of outer segments are observed, and the inner segments show severe signs of degeneration as well. They are greatly shortened and contain many fewer mitochondria than normal. (B) (study group D) shows long, well-organized outer segments from an eye treated with BDNF. Magnification, (A) $\times 4070$; (B) $\times 6900$.

nearly normal morphology. There is, however, always significant space found between the outer segments, even in areas where they are of normal length. Presumably, this is because of two effects: the death of some photoreceptors and the absence of apical processes from the RPE,^{20,21} which normally fill this space.

Outer Segment Length

Figures 5, 6, and 7 present the average outer segment lengths in individual animals used in the study, and Table 2 summarizes the data for all the animals. (Data from both the outer segment length measurements and the subjective rating scale led to the same conclusions. Only the former are presented here.) The data in Figure 5 and Table 2 show that there was no effect of BDNF on outer segment length when it was injected into normal eyes or into those with the lens and vitreous removed. Several observations emerge from the quantitative data in Figures 6 and 7:

1. At both 7 and 28 days, several of the animals, the majority at 28 days, had outer segments that were on average longer than in the PBS-injected controls.
2. Four of 12 (33%) control detachments had no detectable outer segments in any of the 14 regions examined, whereas this occurred in only 2 of 30 (7%) BDNF-treated animals.
3. There was large variability within individual animals. This is significant because in several BDNF-treated animals the average outer segment length was not much greater than in the PBS-injected control detachments, but there were areas within these eyes in which outer segments approached normal length

or even exceeded it. This was never true in the PBS-injected animals.

4. Overall, the outer segments were of greater average length in the 28-day than the 7-day, BDNF-treated animals (Table 2).

5. Seven-day animals with only postdetachment injections had slightly longer outer segments than those with predetachment injections; however, this trend was reversed in the 28-day animals.

6. In both the 7- and 28-day BDNF-treated detachment groups there were animals that had outer segments much longer than in the untreated normal or BDNF-treated animals without detachments. Indeed, four animals had outer segments that measured over 30 μm in length, or twice their length in

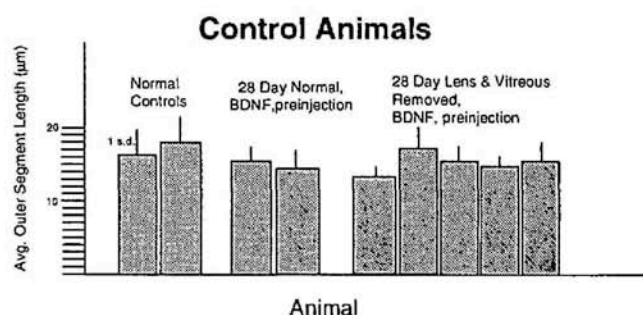


FIGURE 5. Average outer segment lengths in the individual control animals without retinal detachments, showing that BDNF injected into the normal eye had no effect on outer segment length.

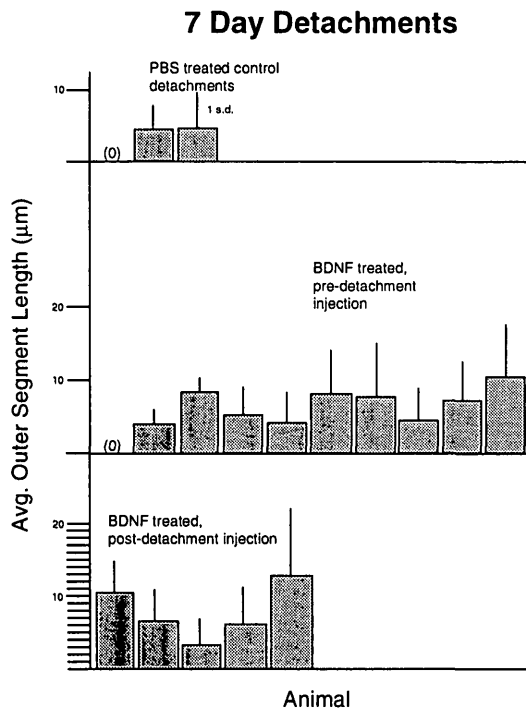


FIGURE 6. Average outer segment lengths in individual animals with 7-day detachments treated with either PBS (*top row*) or BDNF (*bottom two rows*). 0 indicates the complete absence of outer segments in any section. Although not statistically significant (Table 2), overall, the BDNF-treated retinas had longer outer segments than those treated with PBS. There was little difference in outer segment length between retinas treated with predetachment and postdetachment injections.

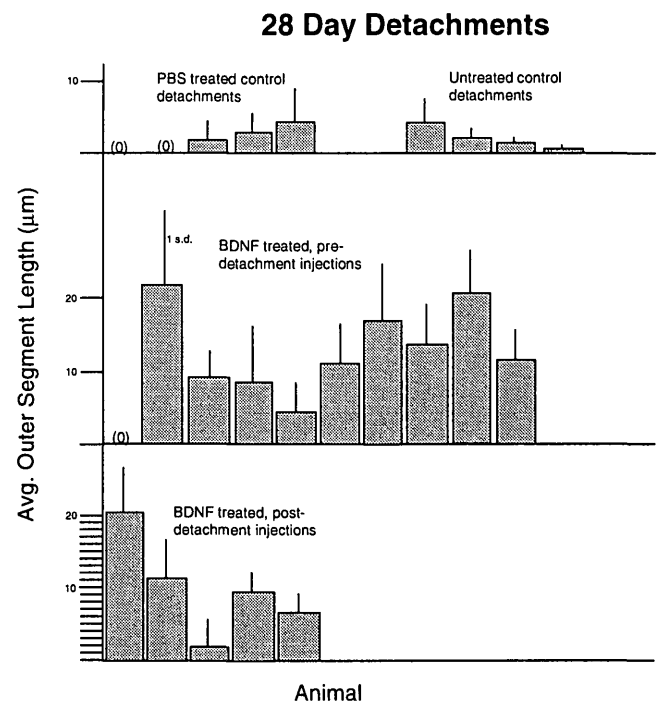


FIGURE 7. Average outer segment lengths in the individual animals with 28-day detachments and treated with PBS (*top row, left group*), left untreated (*top row, right group*), or treated with BDNF (*bottom two rows*). 0 indicates the complete absence of outer segments in any section. As in the 7-day experiments, the BDNF-treated retinas showed much longer outer segments than those treated with PBS. In this case there was a statistically significant difference (Table 2).

the BDNF-treated or normal controls. In two of these animals there were areas with outer segments slightly more than 36 µm in length.

A one-way analysis of variance comparing outer segment length in PBS-, BDNF-, and pretreated versus nonpretreated animals at 7 days showed no statistically significant differences between the groups ($F[2,16] = 2.80; P > 0.05$), whereas at 28 days there was a significant difference ($F[2,17] = 4.368; P < 0.05$). Both the Tukey and Scheffé two-sided *t*-tests showed no significant difference between the 7-day detachment PBS-injected group and either the group receiving the predetachment injection or the group receiving only the postdetachment injection of BDNF. The same tests, however, showed a significant difference in the 28-day animals ($P < 0.05$) between the PBS group and the BDNF-injected animals with pretreatment.

Cell Death

Counts of TUNEL-labeled cells in retinas detached for 3 days and receiving a single injection of BDNF at the time of detachment are shown in Figure 8. Although the total number of TUNEL-labeled cells were reduced in the sampling areas of the BDNF-treated eyes (25.0 versus 39.8), the difference was not statistically significant.

Figure 9 shows a comparison of the ONL cell counts from all the control and experimental animals for the most central area of the superior nasal quadrant. (Data from the more peripheral area show exactly the same trend.) The injection of BDNF into normal eyes or those with the lens and vitreous removed had no effect on ONL counts. There was a substantial

decline in the number of cells, however, after detachment. In the areas sampled, somewhere between one quarter and one third of the photoreceptors were lost after detachment, regardless of whether the eye received PBS or BDNF injections. Comparing the 7- and 28-day detachments suggests that most cell death occurred within the first week, confirming the data

TABLE 2. Summary of Outer Segment Length Measurements

Group	
Control animals	
Normal (n = 2)	17.4 ± 1
28 Day + BDNF (n = 2)	15.2 ± 0.8
28 Day L&V* + BDNF (n = 5)	15.2 ± 1.4
7-day detachments	
+ PBS (n = 3)	2.5 ± 2.6
+ BDNF (predetachment injection; n = 10)	6 ± 3.1
+ BDNF (postdetachment injection; n = 5)	7.8 ± 3.7
28-day detachments	
No injections (n = 4)	2.3 ± 1.7
+ PBS (n = 5)	1.8 ± 1.9
+ BDNF (predetachment injection; n = 10)	12 ± 7.2
+ BDNF (postdetachment injection; n = 5)	10.1 ± 7

* Lens and vitreous removed.

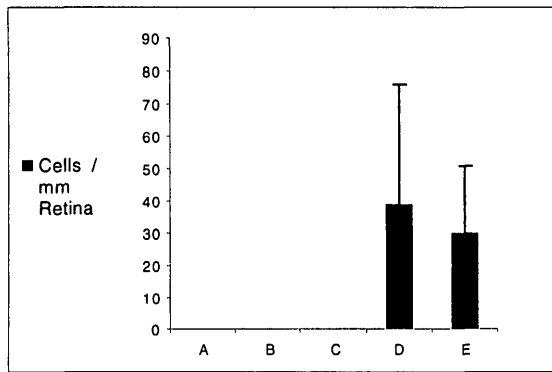


FIGURE 8. The average number of TUNEL-labeled cells per millimeter of retina. A, normal retina ($n = 4$). B, normal retina treated with 50 μ l PBS 3 days before animals were sacrificed ($n = 2$). C, normal retina treated with 100 μ g human recombinant BDNF in PBS 3 days before animals were sacrificed ($n = 2$). D, retina detached for 3 days, treated with 50 μ l PBS at the time of detachment ($n = 3$). E, retina detached for 3 days, treated with 100 μ g human recombinant BDNF in PBS at the time of detachment ($n = 3$). There were no labeled cells in the animals without detachments (A, B, C). The BDNF-treated retinas showed fewer TUNEL-labeled cells, but the difference was not statistically significant. Error bars, 1 SD.

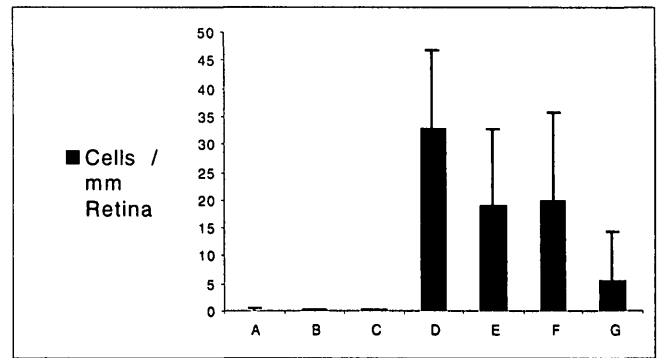


FIGURE 10. The number of anti-Ki67-labeled cells per millimeter of retina. A, B, C, D, E, cells in all retinal layers. F, G, cells only in the inner nuclear layer. A, normal retina ($n = 4$). B, normal retina treated with 50 μ l PBS 3 days before animals were sacrificed ($n = 2$). C, normal retina treated with 100 μ g human recombinant BDNF in PBS 3 days before animals were sacrificed ($n = 2$). D, F, retina detached for 3 days, treated with 50 μ l PBS at the time of detachment ($n = 3$). E, G, retina detached for 3 days, treated with 100 μ g human recombinant BDNF in PBS at the time of detachment ($n = 3$). In this experiment, BDNF significantly reduced the number of labeled cells in the INL (compare bars F and G). Error bars, 1 SD.

in our earlier study of TUNEL.⁷ There was no statistically significant difference between the PBS- and BDNF-injected eyes in the areas sampled.

Proliferation

Nonneuronal cell proliferation is another hallmark response of retinal detachment.^{8,9} Figure 10 shows the number of anti-

Ki67-labeled cells across all retinal layers for nondetached retina (bars A, B, C) and detached retina receiving PBS or BDNF (bars D, E) and those labeled cells specifically lying within the inner nuclear layer (INL; bars F, G). Although the total number of labeled cells (Müller cells, astrocytes, endothelial cells, pericytes, and microglia) was less in the sampled areas of the BDNF-treated eyes (20 versus 32) the difference was not statistically significant. The difference in the numbers of labeled cells within the INL (5 versus 21), however, was statistically significant (Student's *t*-test; $P < 0.001$). The nuclei labeled within the INL are almost certainly all Müller cells, based on their size and location.

Immunocytochemistry

The antibodies used for this study were selected because they provide reliable and characteristic responses in this detachment model. The immunolabeling patterns for all antibodies were highly consistent in the PBS-injected eyes (and identical with those in our previous studies). There was, as expected from the morphologic and quantitative data, variability in the BDNF-treated samples. Here, we illustrate for the BDNF treatment group examples from those eyes that show positive responses—that is, immunolabeling patterns more similar to those in normal retina and unlike those observed in detachments from untreated or PBS-injected eyes. A negative response in the BDNF-injected group would simply be as illustrated for the PBS-injected group.

Anti-rod Opsin. BDNF treatment of eyes without retinal detachments did not affect the pattern of labeling with the Rho4D2 rod opsin antibody (compare Figs. 11A, 11B; also see Ref. 13). There was heavy labeling of the rod outer segments and the Golgi-endoplasmic reticulum of the inner segment and light labeling of the plasma membrane. The change in this labeling pattern that occurred in PBS-injected eyes with detachments was the same as observed in detachments without intraocular injections^{12,13}: continued labeling of the shortened

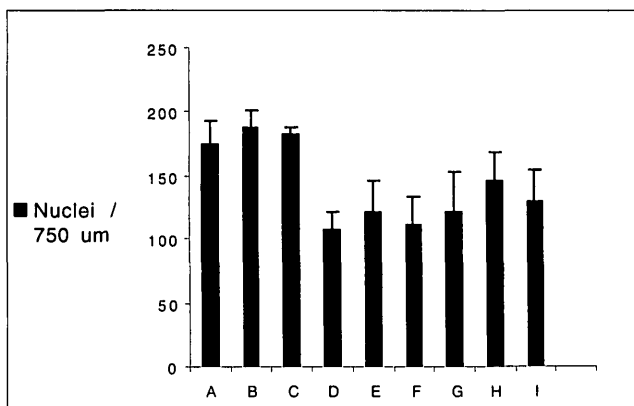


FIGURE 9. The mean number of photoreceptor cells/750 μ m of retinal length in the outer nuclear layer of animals in different conditions taken from the 7- and 28-day BDNF photoreceptor rescue experiment. A, normal retina ($n = 2$). B, normal retina + BDNF (control group I in Table 1). C, lens and vitreous removed + BDNF (control group H in Table 1). D, 7-day detachment + PBS (control group E in Table 1). E, 7-day detachment + BDNF without predetachment injection (experimental group A in Table 1). F, 7-day detachment + BDNF with predetachment injection (experimental group B in Table 1). G, 28-day detachment + PBS (control group F in Table 1). H, 28-day detachment + BDNF without predetachment injection (experimental group C in Table 1). I, 28-day detachment + BDNF with predetachment injection (experimental group D in Table 1). The ONL cell counts were similar in BDNF- and PBS-treated retinas, indicating that BDNF probably did not affect photoreceptor cell loss in these experiments. Error bars, 1 SD.

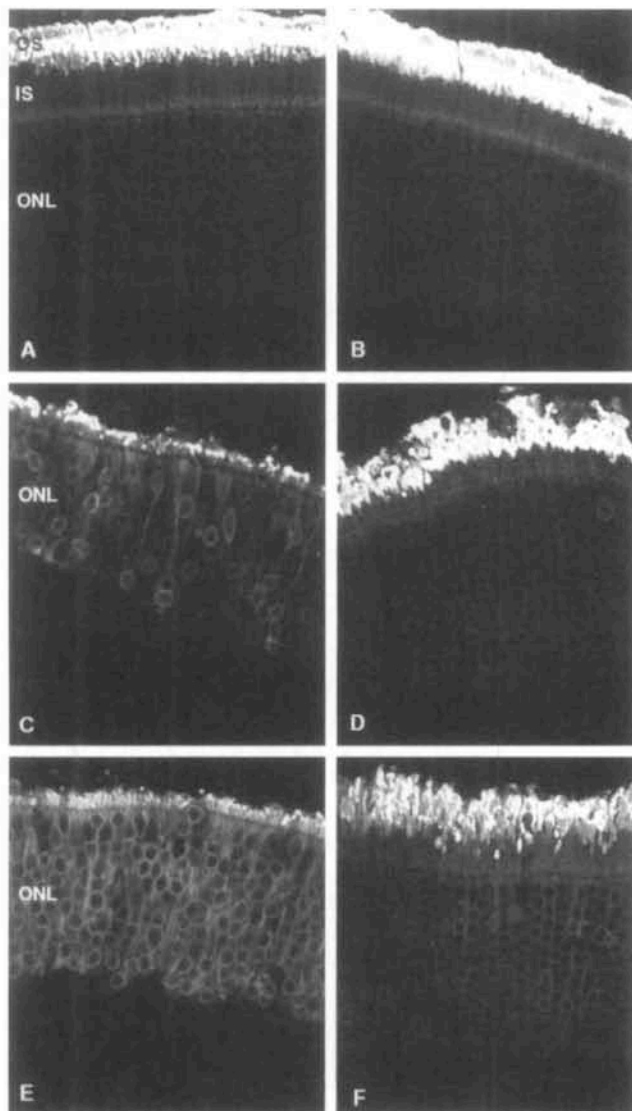


FIGURE 11. Laser scanning confocal micrographs showing the immunolabeling pattern for the antibody to rod opsin. (A) Normal retina. Labeling is limited to that in the outer segments and Golgi-endoplasmic reticulum of the inner segments. Very faint labeling of the plasma membrane of the rod cell bodies is also present. (B) Normal retina treated with BDNF. The same labeling pattern as illustrated in (A). (C) Retina detached for 7 days and treated with PBS. (D) Retina detached for 7 days and treated with BDNF. (E) Retina detached for 28 days and treated with PBS. (F) Retina detached for 28 days and treated with BDNF. Note the very short, disrupted outer segments and extensive plasma membrane labeling in (C) and (E), both characteristic of detached retina. Longer outer segments and much fainter plasma membrane labeling is present in the BDNF-treated retinas (D, F). Each image is a two-dimensional projection of a series of five consecutive images with a single-image plane equal to $1\ \mu\text{m}$ in depth. OS, outer segment layer; IS, inner segment layer; ONL, outer nuclear layer. Magnification, $\times 250$.

outer segments, a more diffuse labeling of the Golgi-endoplasmic reticulum region, and a dramatic increase in labeling of the plasma membrane in the ONL (Figs. 11C, 11E). In the retinas that showed a positive morphologic response to BDNF (Figs. 11D, 11F), the anti-opsin labeling pattern more closely resem-

bled that in the normal retina (Fig. 11A) with a decreased amount of plasma membrane labeling in the ONL.

Anti-phosducin. The antibody to phosducin labeled the photoreceptor inner segments, cell bodies, and synaptic terminals in both normal eyes and normal BDNF-treated eyes (Figs. 12A, 12B). After retinal detachment there was a distinctive increase in the labeling intensity of the inner segments and cell bodies (Figs. 12C, 12E) but a loss of the synaptic-terminal labeling. In the retinas showing a positive morphologic response to BDNF, the increase in anti-phosducin labeling intensity either did not occur or was greatly attenuated (Figs. 12D, 12F). In addition, the labeling of the synaptic terminals in the treated retinas gave a more normal appearance to the layer of terminals (Fig. 12D, 12F).

Anti-synaptophysin. In normal retina (and normal retina treated with BDNF), this antibody distinctively labeled the synaptic terminals of rods and cones in the outer plexiform layer (OPL; Fig. 13A, 13B). When the retina was detached, however, this pattern was rapidly disrupted, which correlated with the loss of synaptic terminals from the photoreceptors (Fig. 13C and Ref. 11). Labeled terminals were not only missing from the OPL but often occurred deep in the ONL (Fig. 13C, arrow). In the detachments treated with BDNF and showing a positive response, there was much more typical labeling of the layer of synaptic terminals, with the layer appearing more intact and organized. The layer of terminals often appeared reduced in width, as expected from the loss of cells. Only occasionally did labeled terminals appear within the ONL in the detached BDNF-treated retinas (Fig. 13D).

Anti-calbindin D. Anti-calbindin D is a marker for neurite outgrowth from horizontal cells,¹¹ an event that begins within 3 days of detachment. This response occurred predictably in the PBS-injected retinas (compare Figs. 14A, 14B, 14C, 14E), where fine anti-calbindin D-labeled processes could be seen extending beyond their usual termination at the layer of photoreceptor synaptic terminals into the outer nuclear layer. It appeared to be suppressed in the animals showing a positive response to BDNF. In the examples shown in Figures 14D and 14F, there are no labeled processes extending beyond the level of the photoreceptor synaptic terminals into the ONL.

Anti-GFAP

The upregulation of GFAP in Müller cells is another reliable response to detachment and occurs concomitantly with the hypertrophy of Müller cell processes.¹⁴ Labeling with anti-GFAP occurred in astrocytes and Müller cell end feet in normal cat retina (Fig. 15A), and three injections of BDNF into the eye did not change this pattern (Fig. 15B). As expected, anti-GFAP labeling greatly increased in the Müller cell cytoplasm in 7- and 28-day detachments (Figs. 15C, 15E). The anti-GFAP-labeled processes extended to the outer limiting membrane and often into the subretinal space by 7 days (also see Ref. 10). At 28 days the labeling intensity increased, labeled processes in the retina became thicker and more extensive, and the number of processes and their size in the subretinal space increased significantly (Fig. 15E, *). Although there was an increase in the expression of GFAP in Müller cells in the retinas showing a positive response to BDNF, the response was greatly attenuated by comparison with that in the PBS-injected eyes (Figs.

15D, 15F). There are fewer labeled processes extending into the retina from the end feet and for the most part, heavy labeling stopped at the level of the OPL in both the 7- and 28-day detachments.

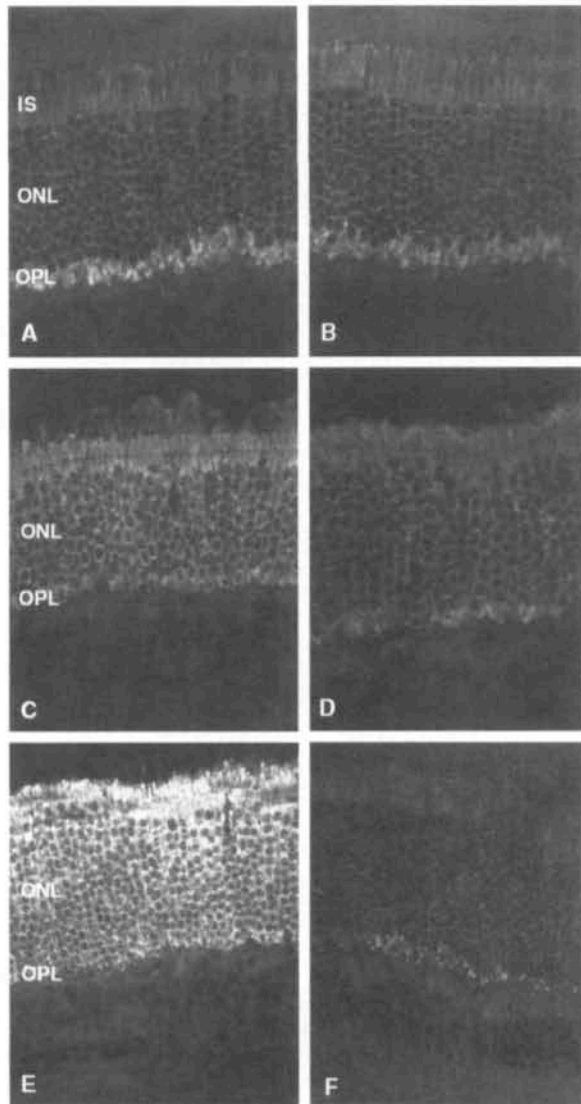


FIGURE 12. Laser scanning confocal micrographs showing the immunolabeling pattern for the antibody to phosducin. (A) Normal retina. The heaviest labeling occurs in the inner segments and synaptic terminals of the photoreceptors, with some labeling of the cell bodies as well. (B) Normal retina treated with BDNF. The same labeling pattern as illustrated in (A). (C) Retina detached for 7 days and treated with PBS. (D) Retina detached for 7 days and treated with BDNF. (E) Retina detached for 28 days and treated with PBS. (F) Retina detached for 28 days and treated with BDNF. When the retina was detached and treated with PBS (C, E), there was a dramatic increase in photoreceptor labeling with this antibody, ranging from the inner segments through the cell bodies. There was also a loss of labeling of synaptic terminals. When the retinas were treated with BDNF (D, F) the labeling pattern more closely resembled that seen in normal retina: There is only a partial loss of synaptic terminal labeling, and the labeling within the ONL was less than in the PBS-treated detachments (C, E). Each image is a two-dimensional projection of a series of five consecutive images with a single-image plane equal to 1 μm in depth. IS, inner segment layer; ONL, outer nuclear layer; OPL, outer plexiform layer. Magnification, $\times 250$.

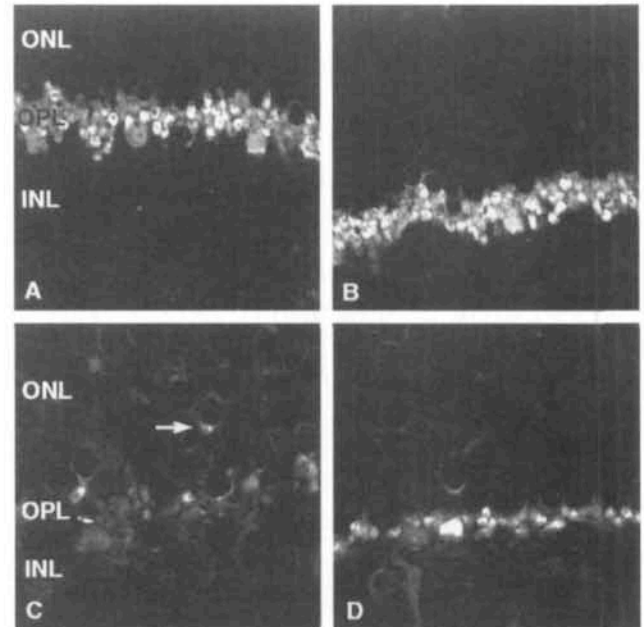


FIGURE 13. Laser scanning confocal micrographs showing the immunolabeling pattern for the antibody to synaptophysin. (A) In normal retina this antibody distinctively labeled the synaptic terminals of rods and cones. (B) Normal retina treated with BDNF. The same labeling pattern as in (A). (C) Retina detached for 28 days and treated with PBS. (D) Retina detached for 28 days and treated with BDNF. After detachment there was a rapid loss of photoreceptor synaptic terminals from the OPL and some labeled terminals appear deep in the ONL (C, arrow). There was an obvious preservation of anti-synaptophysin-labeled terminals in the 28-day BDNF-treated retina (D). Each image is a two-dimensional projection of a series of 10 consecutive images with a single-image plane equal to 1 μm in depth. Magnification, $\times 600$.

Immunocytochemical Ratings

Figure 16 shows the results of the ratings used to compare the antibody labeling patterns, thus providing an overview of the differences between the BDNF-treated and untreated retinas. The ratings were derived from all retinas, not only those showing a positive photoreceptor response. A comparison of the data presented for each antibody in Figure 16 shows that the responses for the rod opsin, phosducin, and synaptophysin immunolabeling are approximately 50% of that in the untreated eyes, whereas that for calbindin D was approximately 28%, and for GFAP approximately 67%. Most important, the data from the ratings led to the same conclusions as those formed from the histologic observations and outer segment measurements.

DISCUSSION

Effects on Photoreceptor Cells

In other models of retinal degeneration, BDNF^{3,4} or similar molecules (ciliary neurotrophic factor [CNTF]^{3,4,23,24} and basic fibroblast growth factor [bFGF]^{1,2,22}) delay the degeneration and apoptotic death of photoreceptor cells.²⁵⁻²⁸ Some photoreceptors die by apoptosis after retinal detachment.⁷ Our data suggest that BDNF did not significantly prevent the loss of photoreceptors or affect apoptosis after detachment. The number of cells in the ONL did not differ significantly between

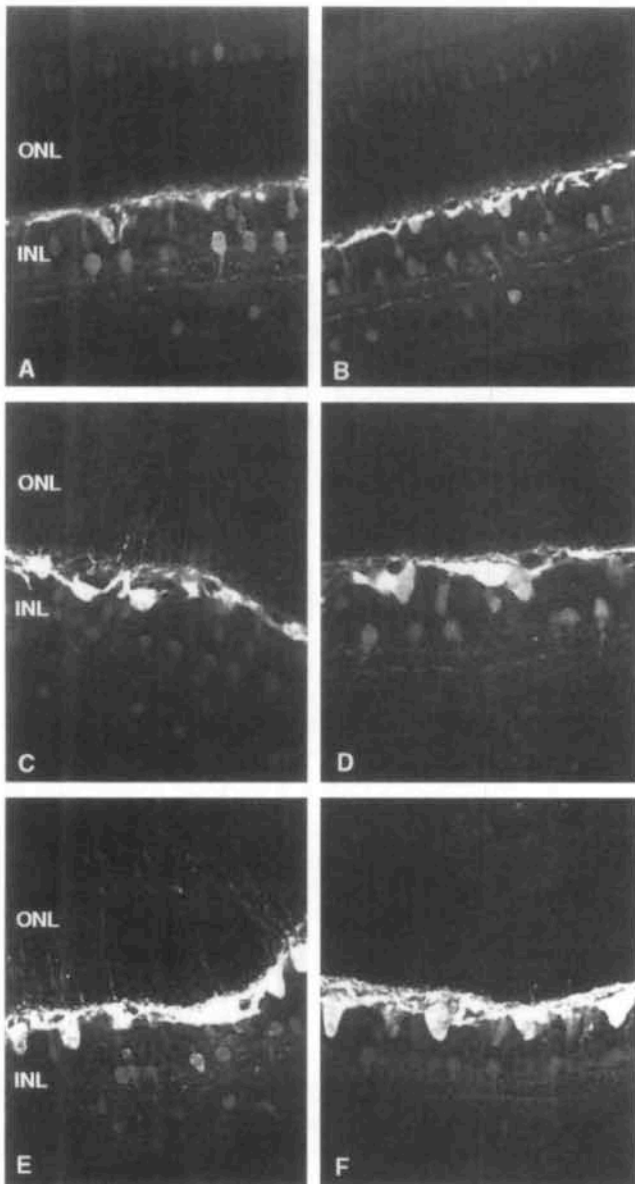


FIGURE 14. Laser scanning confocal micrographs showing the immunolabeling pattern for the antibody to calbindin (**D**). (**A**) Normal retina. The antibody labeled horizontal cells most heavily, with fainter labeling of some other INL cells and cones. (**B**) Normal retina treated with BDNF. The same labeling pattern as illustrated in (**A**). (**C**) Retina detached for 7 days and treated with PBS. (**D**) Retina detached for 7 days and treated with BDNF. (**E**) Retina detached for 28 days and treated with PBS. (**F**) Retina detached for 28 days and treated with BDNF. When the retina was detached and treated with PBS only (**C**, **E**), there were extensive calbindin D-positive outgrowths from the horizontal cells into the ONL. When the retina was treated with BDNF, this response was dramatically reduced, even in areas where there was evidence of photoreceptor degeneration (**D**, **F**). Each image is a two-dimensional projection of a series of 10 consecutive images with a single-image plane equal to 1 μ m in depth. Magnification, $\times 200$.

BDNF-treated and untreated retinas. Although the data were obtained from a separate experiment in which we provided BDNF at the time of detachment and examined the results 3 days later, this conclusion is supported by the absence of an effect on apoptosis. Thus, the effect of BDNF differed signifi-

cantly in the detachment model from that observed in the other models of photoreceptor degeneration.

Based on data from the 7-day experiments, BDNF did not appear to maintain outer segment structure; rather, it appeared to maintain the overall structural organization of the remainder of the cell, including that of the synaptic terminal. However, a

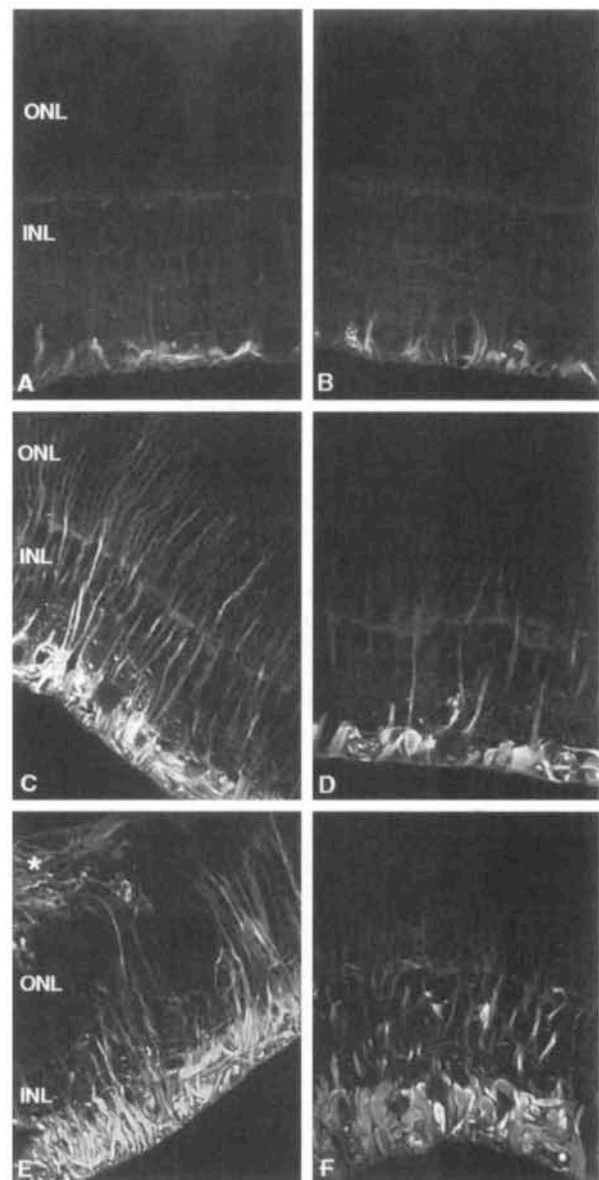


FIGURE 15. Laser scanning confocal micrographs showing the immunolabeling pattern for the antibody to GFAP. (**A**) Normal retina. The antibody labeled the end foot region of Müller cells and retinal astrocytes. (**B**) Normal retina treated with BDNF. The same labeling pattern as illustrated in (**A**). (**C**) Retina detached for 7 days and treated with PBS. (**D**) Retina detached for 7 days and treated with BDNF. (**E**) Retina detached for 28 days and treated with PBS. (**F**) Retina detached for 28 days and treated with BDNF. When the retina was detached and left untreated or treated with PBS (**C**, **E**), there was a rapid and extensive increase in labeling with this antibody associated with the hypertrophy of the Müller cell processes (**C**, **E**). In (**E**) there is a characteristic Müller cell scar in the subretinal space (*). When the retina was treated with BDNF, this response was dramatically reduced (**D**, **F**). Each image is a two-dimensional projection of a series of 10 consecutive images with a single-image plane equal to 1 μ m in depth. Magnification, $\times 200$.

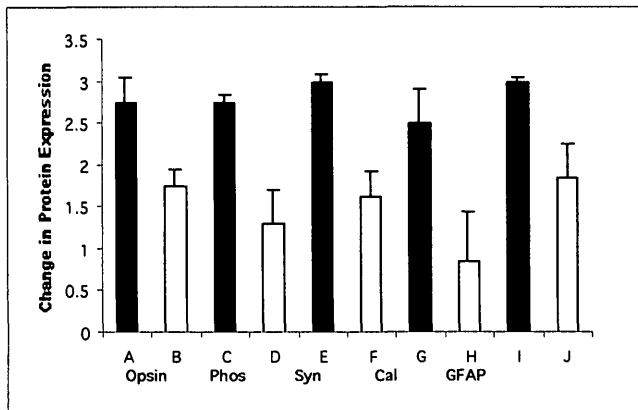


FIGURE 16. The pairs of bars represent the ratings comparing retina detached for 28 days and treated with PBS (solid bars A, C, E, G, I) or BDNF (open bars B, D, F, H, J) with retina detached for 28 days and left untreated. A rating of 0 would be equivalent to the expected pattern in normal retina, whereas a rating of 3 would be equivalent to the maximum response in a 28-day, untreated detachment. A, B, anti-rod opsin; C, D, anti-phosducin (Phos); E, F, anti-synaptophysin (Syn); G, H, anti-calbindin D (Cal); I, J, anti-GFAP. Error bars, 1 SD.

comparison of results in the 28-day BDNF-treated eyes with those in PBS-treated eyes and with the results in the 7-day experiments suggests that the neurotrophin may promote robust outer segment regeneration. Although there was not a statistically significant difference in average outer segment length between treated and untreated retinas in the 7-day detachment group, we still believe the differences are important, based on our observations over many years of using this model. Outer segments with the length and morphology of those observed in numerous areas of the BDNF-treated retinas have rarely been observed in retinas detached for 7 days. The difference became even more apparent in the 28-day experiments in which there was a statistically significant effect.

Our morphologic observations and data showing that outer segments were longer in the 28-day BDNF-treated groups than in the 7-day groups led us to conclude that outer segments began degenerating, but in the presence of BDNF began regenerating, even though they remain detached. Data from reattachment experiments²⁹ show that the assembly rate of primate rod outer segments is slowed for weeks. In the animals with 7-day detachments and no predetachment injection of BDNF, the outer segments had a maximum of 4 days to regenerate after injection of BDNF. If we assume that these degenerated to 2.5 μm (the average length in PBS controls) before receiving BDNF, and began regenerating immediately thereafter, it would require a minimum renewal rate of 1.3 $\mu\text{m}/\text{day}$ for them to reach a length of 7.8 μm . The longest outer segments (36 μm) occurred in two 28-day animals receiving BDNF. If we assume that disc shedding is minimal during detachment³⁰ and that these outer segments degenerated to 2.3 μm (the value from the PBS-controls) by day 3, then they grew 33.7 μm from day 3 to day 28, or an average of 1.3 $\mu\text{m}/\text{day}$, the same rate estimated in the 7-day experiment, and only slightly more than the rate of 1.15 $\mu\text{m}/\text{day}$ estimated for recently reattached primate rods.²⁹ Autoradiography shows that detached photoreceptors transport radiolabeled proteins to the outer segment base.¹² It appears that the BDNF allowed the assembly of these components into an outer segment, albeit at a rate less than in

normal cats³¹ but close to that observed in reattached primate rods.

The increased presence of rod opsin in the plasma membrane is a sensitive indicator of the status of the outer segment.¹³ In general, we found much less intense labeling of the rod plasma membrane in the BDNF-treated retinas, an observation that correlated well with the presence of longer outer segments, thus providing valuable, independent confirmation of the morphologic observations.

Of equal importance to maintaining functionality in the retina is the presence of photoreceptor synaptic terminals. It seems likely that terminals were maintained in the differentiated state by the presence of BDNF, rather than regenerating. Based on the synaptophysin data, the layer of synaptic terminals was always thinner than normal in the BDNF-treated animals with detachments, but there were still significantly more terminals in the treated animals than in the PBS-treated or nontreated detachments. There were still significant numbers of synaptophysin-positive terminals present in untreated retinas 3 days after detachment,¹¹ and we therefore probably would not expect to see a large difference between predetachment and postdetachment BDNF-treated animals, even if the predetachment injection provided further protection against degeneration, and, indeed, that was what we observed. Also, there was little difference between the appearance of the synaptic zone between 7 and 28 days, which may not have been expected if BDNF promoted regeneration of terminals.

The phosducin labeling data provided additional evidence that BDNF maintained the overall state of the surviving photoreceptors. This protein was reliably upregulated after detachment, an observation also reported in a canine inherited retinal dystrophy.³² The difference in the levels of labeling in the ONL between treated and untreated animals was dramatic, with only the occasional cell showing the characteristic increase in labeling intensity in the treated retinas. Although not quite as distinct in its staining pattern, these data independently supported the conclusions from the anti-synaptophysin data.

BDNF can have different effects on different populations of neurons in different experimental conditions. In some of the inherited retinal degenerations it delays photoreceptor degeneration. It does not, however, in a feline model of inherited rod-cone dystrophy.²⁴ Nor does BDNF slow the collapse of outer segments in isolated rods, whereas CNTF, bFGF, and glial cell-line derived neurotrophic factor (GDNF) all do.³³ BDNF can promote the survival of cultured,³⁴ axotomized, or otherwise injured retinal ganglion cells,³⁵⁻³⁸ and its support of neuron survival elsewhere in the central nervous system is well established.³⁹ It can also promote events in nerve cell maturation including: neurite outgrowth,⁴⁰⁻⁴⁶ axonal differentiation and elongation,^{47,48} dendritic growth and differentiation,^{49,50} and synaptic efficacy.^{45,48,51-54} Thus, our results are consistent with numerous reports on the effect of BDNF and its possible influence on the state of differentiation of a neuron, even though it may not protect the cells from dying.

Effects on Second-Order Neurons

The outgrowth of neurites by horizontal cells is a reliable and rapid response to detachment.¹⁰ BDNF inhibited this change in both the 7- and 28-day treatment groups. The suppression of neurite outgrowth by BDNF appeared to be independent of the effect on photoreceptors; we observed a suppression of this response in areas showing severe photoreceptor degeneration.

Effects on Müller Cells

Retinal detachment produces a full gliotic response from Müller cells including proliferation, hypertrophy, and an upregulation of intermediate filament proteins.^{5-7,10,14,15} In both the 7- and 28-day experiments there was notably less labeling with the antibody to GFAP in the BDNF-treated detachments, with labeled processes rarely extending beyond the OPL, confirming our impression of less hypertrophy by Müller cells in the treated eyes. Although the experimental design differed from the rescue study, the effect on Müller cell proliferation in the 3-day detachments was dramatic, with the treated eyes having less than 25% of the number of proliferating cells. It appears that BDNF inhibited each component of the gliotic response from these cells, and this would explain why we observed fewer gliotic scars in the treated detachments. Another factor known to rescue photoreceptors, bFGF, stimulates both Müller cell proliferation and intermediate filament upregulation.⁵⁵ CNTF (and its analogue, axokine) also appear to upregulate the expression of GFAP in Müller cells.^{24,56-58} This may be an important consideration if these molecules are to be used therapeutically, because glial scar formation can be a serious complication of retinal detachment and reattachment.

Adverse Effects

Some factors have been reported to produce retinal rosettes or folds,^{4,24} and specifically minimal posterior subcapsular cataract, in the feline eye.²⁴ Our experience confirmed that in earlier studies, inasmuch as BDNF had no discernible adverse effects in any of the controls.^{3,4}

Variability

LaVail et al.⁴ provide an extensive discussion of the variability encountered in experiments similar to these. Thus, the degree of variability found by us was not unusual. Many uncontrolled elements can introduce variability in all these models.⁴ A significant problem with these factors is that they do not cross the blood-retina barrier, thus requiring direct intraocular injection. Leakage of even relatively small amounts of factor, a lack of uniform retinal distribution, and the fact that we know little about their biologic half-lives⁵⁹ are all of concern. An uneven distribution across the relatively large cat eye could explain the patchy nature of the positive results in several of the eyes. It is difficult to determine the precise height of a detachment, because the retina can settle down against the RPE during dissection and fixation. If BDNF stimulates the RPE to release some factor (e.g., bFGF⁶⁰), that in turn effects the retina, then, the distance of separation may be critical to the efficacy of the treatment. Focal injury has also been shown to rescue photoreceptors.⁶¹ However, in the control animals with detachments that received injections of PBS we did not observe any rescue effect. This could be a species difference, or perhaps more likely, the background trauma produced by retinal detachment simply overwhelmed any localized effect produced by the intraocular injections.

We concur with LaVail et al.⁴ who argue that it is the presence of positive results in experiments of this type that are important. In 15 years of studying this particular model we have never seen photoreceptors in 28-day detachments that resembled those occurring in 17 of 20 of the BDNF-treated retinas. Moreover, the antibodies used are sensitive and reliable indicators of the cellular responses to detachment and fully

supported the morphologic observations. Because of the significant variability, the statistical tests tended to minimize the differences between the groups. Nevertheless, we believe the positive effects should not be overshadowed by the statistical analysis and that it is valid to emphasize the positive effects when interpreting the results.

Mechanisms of Action

The mechanism through which trophic factors act to protect photoreceptors is still unknown. The receptor *trkB* is regarded as the primary functional receptor for BDNF, but it also binds to a low-affinity nerve growth factor receptor.^{62,63} To date, most published data do not favor the presence of functional *trkB* receptors on photoreceptors, horizontal cells, or Müller cells.^{34,37,47,64-67} Thus, the effects described here currently must be explained through an indirect action, perhaps through stimulating other retinal cells to release factors that then act to produce the observed effects, or by the presence of a previously undescribed receptor. The retina is known to express two factors with potent photoreceptor rescue properties, bFGF and CNTF,⁶⁸⁻⁷¹ and BDNF can stimulate the RPE to produce bFGF.⁶⁰ Although there is some evidence for the low-affinity receptor on Müller cells, its function remains unknown.^{72,73}

CONCLUSIONS

The present data show that exogenous BDNF had specific and important effects in a model of retinal detachment that make it a candidate for clinical use to improve the ability of the retina to recover. Even in the face of significant variability, the fact remains that we found remarkably well-organized, long outer segments in conditions in which they should not occur and that we found other effects such as the preservation of synaptic structures and a reduction in gliosis. However, there remain many unresolved issues. We have no data indicating a relationship between the dose of the factor and the response, nor do we currently have a way of improving the distribution of the dose with time or across the retina. We do not know whether BDNF improves regeneration once the retina is reattached, although those specific experiments are under way. Establishing the effects of the factor, whether positive or negative, on reattached retina is important. The most serious effects of detachment occur when the fovea is involved. We have little information on the effects of BDNF on cones, because they are not populous in the cat retina and tend to degenerate very quickly,⁷⁴ before the earliest datapoint in the study. We selected BDNF because data from other models indicated it to be potent in protecting photoreceptors with no identifiable adverse effects. Other factors may be as or more potent than BDNF under certain conditions.^{4,33,24,75} It is important to pursue these questions because of the growing evidence that molecules of this type may have the ability to provide new treatments for retinal degenerative diseases.

Acknowledgments

The authors thank Cory Newton, P. J. Kappel, Cherlin Johnson, Rick Hussey, and Jared Younger for technical help and Matthew LaVail, the late Roy Steinberg, and Jesse Cedarbaum for invaluable advice in planning the experiments.

References

- Faktorovich EG, Steinberg RH, Yasumura D, Matthes MT, LaVail MM. Photoreceptor degeneration in inherited retinal dystrophy delayed by basic fibroblast growth factor. *Nature*. 1990;347:83-86.
- Faktorovich EG, Steinberg RH, Yasumura D, Matthes MT, LaVail MM. Basic fibroblast growth factor and local injury protect photoreceptors from light damage in the rat. *J Neurosci*. 1992;12:3554-3567.
- LaVail MM, Unoki K, Yasumura D, Matthes MT, Yancopoulos GD, Steinberg RH. Multiple growth factors, cytokines and neurotrophins rescue photoreceptors from the damaging effects of constant light. *Proc Natl Acad Sci USA*. 1992;89:11249-11253.
- LaVail MM, Yasumura D, Matthes MT, et al. Protection of mouse photoreceptors by survival factors in retinal degenerations. *Invest Ophthalmol Vis Sci*. 1998;39:592-602.
- Fisher SK, Anderson DH. Cellular effects of detachment on the neural retina and retinal pigment epithelium. In: Ryan SJ, ed. *Retina*. Vol 3. 2nd ed., St. Louis: CV Mosby; 2019-2061.
- Erickson PA, Fisher SK, Anderson DH, Stern WH, Borgula GA. Retinal detachment in the cat: the outer nuclear and outer plexiform layers. *Invest Ophthalmol Vis Sci*. 1983;24:927-943.
- Cook B, Lewis GP, Fisher SK, Adler R. Apoptotic photoreceptor degeneration in an experimental model of retinal detachment. *Invest Ophthalmol Vis Sci*. 1995;36:990-996.
- Fisher SK, Erickson PA, Lewis GP, Anderson DH. Intraretinal proliferation induced by retinal detachment. *Invest Ophthalmol Vis Sci*. 1991;32:1739-1748.
- Geller SC, Lewis GP, Anderson DH, Fisher SK. Use of the MIB-1 antibody for detecting proliferating cells in the retina. *Invest Ophthalmol Vis Sci*. 1995;36:737-743.
- Lewis GP, Guérin CJ, Anderson DH, Matsumoto B, Fisher SK. Experimental retinal detachment causes rapid changes in the expression of glial cell proteins. *Am J Ophthalmol*. 1994;118:368-376.
- Lewis GP, Linberg KA, Fisher SK. Neurite outgrowth from bipolar and horizontal cells after experimental retinal detachment. *Invest Ophthalmol Vis Sci*. 1998;39:424-434.
- Lewis GP, Erickson PA, Anderson DH, Fisher SK. Opsin distribution and protein incorporation in photoreceptors after experimental retinal detachment. *Exp Eye Res*. 1992;53:629-640.
- Fariss RN, Molday RS, Fisher SK, Matsumoto B. Evidence from normal and degenerating photoreceptors that two outer segment integral membrane proteins have separate transport pathways. *J Comp Neurol*. 1997;387:148-156.
- Erickson PA, Fisher SK, Anderson DH, Guérin CJ, Kaska D. Glial fibrillary acidic protein increases in Muller cells after retinal detachment. *Exp Eye Res*. 1987;44:37-48.
- Lewis GP, Erickson PA, Guérin CJ, Anderson DH, Fisher SK. Changes in the expression of specific Müller cell proteins during long-term retinal detachment. *Exp Eye Res*. 1989;49:93-111.
- Lewis GP, Matsumoto B, Fisher SK. Changes in the organization and expression of cytoskeletal proteins during retinal degeneration induced by retinal detachment. *Invest Ophthalmol Vis Sci*. 1995;36:2404-2416.
- Anderson DH, Guérin CJ, Erickson PA, Stern WH, Fisher SK. Morphological recovery in the reattached retina. *Invest Ophthalmol Vis Sci*. 1986;27:168-183.
- Matsumoto B, Hale IL. Preparation of retinas for studying photoreceptors with confocal microscopy. *Methods Neurosci*. 1993;15:54-71.
- Anderson DH, Stern WH, Fisher SK, Erickson PA, Borgula GA. Retinal detachment in the cat: the pigment epithelial-photoreceptor interface. *Invest Ophthalmol Vis Sci*. 1983;24:906-926.
- Steinberg RH, Wood I. Pigment epithelial cell ensheathment of cone outer segments in the retina of the domestic cat. *Proc R Soc Lond B Biol Sci*. 1974;1187:461-478.
- Fisher SK, Steinberg RH. Origin and organization of pigment epithelial apical projections to cones in cat retina. *J Comp Neurol*. 1982;206:131-145.
- Masuda K, Watanabe I, Unoki K, Ohba N, Maramatsu T. Functional rescue of photoreceptors from the damaging effects of constant light by survival-promoting factors in the rat. *Invest Ophthalmol Vis Sci*. 1995;36:2142-2146.
- Cayouette M, Gravel C. Adenovirus-mediated gene transfer of ciliary neurotrophic factor can prevent photoreceptor degeneration in the retinal degeneration (rd) mouse. *Hum Gene Ther*. 1997;8:423-430.
- Chong NHV, Alexander RA, Waters L, Barnett KC, Bird AC, Luthert PJ. Repeated injections of a CNTF analogue lead to long-term photoreceptor survival in hereditary retinal degeneration. *Invest Ophthalmol Vis Sci*. 1999;40:1298-1305.
- Tso MOM, Zhang C, Abler AS, Chang CJ, Wong F, Chang GQ, Lam TT. Apoptosis leads to photoreceptor degeneration in inherited retinal dystrophy of RCS rats. *Invest Ophthalmol Vis Sci*. 1994;35:2693-2699.
- Shahinfar S, Edward DP, Tso MOM. A pathologic study of photoreceptor cell death in retinal photic injury. *Curr Eye Res*. 1991;10:47-59.
- Chang G-Q, Hao Y, Wong F. Apoptosis: final common pathway of photoreceptor death in rd, rds, and rhodopsin mutant mice. *Neuron*. 1993;11:595-605.
- Lolley RN, Rong H, Craft CM. Linkage of photoreceptor degeneration by apoptosis with inherited defect in phototransduction. *Invest Ophthalmol Vis Sci*. 1994;35:358-362.
- Guérin CJ, Lewis GP, Fisher SK, Anderson DH. Recovery of photoreceptor outer segment length and analysis of membrane assembly rates in regenerating primate photoreceptor outer segments. *Invest Ophthalmol Vis Sci*. 1993;34:175-183.
- William DS, Fisher SK. Prevention of rod disk shedding by detachment from the retinal pigment epithelium. *Invest Ophthalmol Vis Sci*. 1987;28:184-187.
- Fisher SK, Pfeffer BP, Anderson DH. Both rod and cone disc shedding are related to light onset in the cat. *Invest Ophthalmol Vis Sci*. 1983;24:844-856.
- Gropp KE, Huang JC, Aguirre GD. Differential expression of photoreceptor-specific proteins during disease and degeneration in the progressive rod-cone degeneration (prcd) retina. *Exp Eye Res*. 1997;64:875-86.
- Carwile ME, Culbert RB, Sturdivant RL, Kraft TW. Rod outer segment maintenance is enhanced in the presence of bFGF, CNTF and GDNF. *Exp Eye Res*. 1998;66:791-805.
- Johnson JE, Barde YA, Schwab M, Thoenen H. Brain-derived neurotrophic factor supports the survival of cultured rat retinal ganglion cells. *J Neurosci*. 1986;6:3031-3038.
- Klöcker N, Cellerino A, Bähr M. Free radical scavenging and inhibition of nitric oxide synthase potentiates the neurotrophic effects of brain-derived neurotrophic factor on axotomized retinal ganglion cells in vivo. *J Neurosci*. 1989;18:1038-1046.
- Mansour-Robaey S, Clarke DB, Wang YC, Bray GM, Aguayo AJ. Effects of ocular injury and administration of brain-derived neurotrophic factor on survival and regrowth of axotomized retinal ganglion cells. *Proc Natl Acad Sci USA*. 1994;91:1632-1636.
- Mey J, Thanos S. Intravitreal injections of neurotrophic factors support the survival of axotomized retinal ganglion cells in adult rats in vivo. *Brain Res*. 1993;602:304-317.
- Thanos S, Bahr M, Barde YA, Vanselow J. Survival and axonal elongation of adult rat retinal ganglion cells: in vitro effects of lesioned sciatic nerve and brain-derived neurotrophic factor (BDNF). *Eur J Neurosci*. 1989;1:19-26.
- Cellerino A, Pinzón-Duarte G, Carroll P, Köhler K. Brain-derived neurotrophic factor modulates the development of the dopaminergic network in the rodent retina. *J Neurosci*. 1998;18:3351-3362.
- Rickman DW, Bowes-Rickman C. Suppression of the trk-B expression by antisense oligonucleotides alters a neuronal phenotype in the rod pathway of the developing rat retina. *Proc Natl Acad Sci USA*. 1996;93:12546-12569.
- Jones KR, Farinas I, Backaus C, Reichardt LF. Targeted disruption of the BDNF gene perturbs brain and sensory neuron development but not motor neuron development. *Cell*. 1994;76:989-999.
- Lindsay RM, Rohrer H. Placodal sensory neurons in culture: no-dose ganglion neurons are unresponsive to NGF, lack NGF receptors but are supported by liver-derived neurotrophic factor. *Dev Biol*. 1985;112:30-48.

42. Ahmed S, Reynolds BA, Weiss S. BDNF enhances the differentiation but not the survival of CNS stem cell-derived neuronal precursors. *J Neurosci.* 1995;15:5765-5778.
43. Cellerino A, Maffei L. The action of neurotrophins in the development and plasticity of the visual cortex. *Prog Neurobiol.* 1996;49:53-71.
44. Marty S, Carroll P, Cellerino A, Castren E, Staiger V, Thoenen H, Lindholm D. Brain-derived neurotrophic factor promotes the differentiation of various hippocampal nonpyramidal neurons, including Cajal-Retzius cells, in organotypic slice cultures. *J Neurosci.* 1996;16:675-687.
45. Braun S, Croizat B, LaGrange MC, Warter JM, Poindron P. Neurotrophins increase motoneurons' ability to innervate skeletal muscle fibers in rat spinal cord-human muscle cocultures. *J Neurol Sci.* 1996;136:17-23.
46. Cohen-Cory S, Fraser S. Effects of brain-derived neurotrophic factor on optic axon branching and remodeling in vivo. *Nature.* 1995;378:461-489.
47. Segal RA, Pomeroy SL, Stiles CD. Axonal growth and fasciculation linked to differential expression of BDNF and NT3 receptors in developing cerebellar granule cells. *J Neurosci.* 1995;15:4970-4981.
48. McAllister KA, Lo DC, Katz LC. Neurotrophins regulate dendritic growth in developing visual cortex. *Neuron.* 1995;15:791-803.
49. McAllister KA, Katz LC, Lo DC. Opposing roles for endogenous BDNF and NT-3 in regulating cortical dendritic growth. *Neuron.* 1997;18:767-778.
50. Kuchel G, Miller FD. Synaptic innervation density is regulated by neuron-derived BDNF. *Neuron.* 1997;18:2657-2667.
51. Lessmann V, Gottmann K, Heumann R. BDNF and NT-4/5 enhanced glutamatergic transmission in cultured hippocampal neurons. *Neuroreport.* 1994;6:21-25.
52. Kang H, Schuman EM. Long-lasting neurotrophin-induced enhancement of synaptic transmission in the adult hippocampus. *Science.* 1995;267:1658-1662.
53. Wang T, Xie S, Lu B. Neurotrophins promote maturation of developing neuromuscular synapses. *J Neurosci.* 1995;15:4795-4805.
54. Lewis GP, Erickson PA, Guérin CJ, Anderson DH, Fisher SK. Basic fibroblast growth factor: a potential regulator of proliferation and intermediate filament expression in the retina. *J Neurosci.* 1992;12:3968-1978.
55. Kahn MA, Huang CJ, Caruso A, et al. Ciliary neurotrophic factor activates JAK/Stat signal transduction cascade and induces transcriptional expression of glial fibrillary acidic protein in glial cells. *J Neurochem.* 1997;68:1413-1423.
56. Sarthy V, Frodjan SJ, Wang Y, Smith SB. Cytokine-mediated neuron-glia signaling in the retina [ARVO Abstract]. *Invest Ophthalmol Vis Sci.* 1998;39(4):S452. Abstract nr 2073.
57. Levison SW, Ducceschi MH, Young GM, Wood TL. Acute exposure to CNTF in vivo induces multiple components of reactive gliosis. *Exp Neurol.* 1996;141:256-268.
58. Herzog KH, von Bartheld CS. Contributions of the optic tectum and the retina as sources of brain-derived neurotrophic factor for retinal ganglion cells in the chick embryo. *J Neurosci.* 1998;18:2891-2906.
59. Hackett SF, Schoenfeld CL, Freund J, Gottsch JD, Bhargava S, Campochiaro PA. Neurotrophic factors, cytokines and stress increase expression of basic fibroblast growth factor in retinal pigmented epithelial cells. *Exp Eye Res.* 1997;64:865-873.
60. Silverman MS, Hughes SE. Photoreceptor rescue in the RCS rat without pigment epithelium transplantation. *Curr Eye Res.* 1990;9:183-191.
61. Rodriguez-Tebar A, Dechant G, Barde YA. Binding of brain-derived neurotrophic factor to the nerve growth factor receptor. *Neuron.* 1990;4:487-492.
62. Carter BD, Kaltschmidt C, Kaltschmidt B, et al. Selective activation of NF-kappa B by nerve growth factor through the neurotrophin receptor p75. *Science.* 1996;272:542-545.
63. Perez MTR, Caminos E. Expression of brain-derived neurotrophic factor and of its functional receptor in neonatal and adult rat retina. *Neurosci Lett.* 1995;183:96-99.
64. Rickman DW, Brecha CB. Expression of the proto-oncogene, trk, receptors in the developing rat retina. *Vis Neurosci.* 1995;12:215-222.
65. Liu ZZ, Zhu LQ, Eide FF. Critical role of TrkB and brain-derived neurotrophic factor in the differentiation and survival of retinal pigment epithelium. *J Neurosci.* 1997;17:8749-55.
66. Cao W, Wen R, Li F, LaVail M, Steinberg R. Mechanical injury increases bFGF and CNTF mRNA expression in the mouse retina. *Exp Eye Res.* 1997;65:241-248.
67. Vecino E, Caminos E, Ugarte M, Martin-Zanca D, Osborne NN. Immunohistochemical distribution of neurotrophins and their receptors in the rat retina and the effects of ischemia and reperfusion. *Gen Pharmacol.* 1998;30:305-313.
68. Cao W, Li F, LaVail M, Steinberg R. Development of injury-induced gene expression of bFGF, FGFR-1, CNTF and GFAP in rat retina [ARVO Abstract]. *Invest Ophthalmol Vis Sci.* 1997;38(4):S604. Abstract nr 2813.
69. Kostyk S, D'Amore P, Herman I, Wagner J. Optic nerve injury alters basic fibroblast growth factor localization in the retina and optic tract. *J Neurosci.* 1994;14:1442-1449.
70. Liu C, Peng M, Latics A, Wen R. Preconditioning with bright light evokes a protective response against light damage in the rat retina. *J Neurosci.* 1998;18:1337-1344.
71. Carmignoto G, Comelli MC, Candeo P, Caviccholi L, Yan Q, Merighi A, Maffei L. Expression of NGF receptor and NGF receptor mRNA in the developing and adult rat retina. *Exp Neurol.* 1991;111:302-311.
72. Schatteman GC, Gibbs L, Lanahan AA, Claude P, Bothwell M. Expression of NGF receptor in the developing and adult primate central nervous system. *J Neurosci.* 1988;8:860-73.
73. Rex TS, Lewis GP, Fisher SK. Rapid loss of blue and red/green cone opsin immunolabeling following experimental retinal detachment [ARVO Abstract]. *Invest Ophthalmol Vis Sci.* 1997;38(4):S35. Abstract nr 62.
74. Lewis GP, Fisher SK. Glial cell-line derived neurotrophic factor (GDNF): retinal distribution and rescue effects on photoreceptors following experimental retinal detachment [ARVO abstract]. *Invest Ophthalmol Vis Sci.* 1998;39(4):S572. Abstract nr 2647.