Proceedings of the 2005 IEEE
Engineering in Medicine and Biology 27th Annual Conference
Shanghai, China, September 1-4, 2005

Image Segmentation, Registration and Visualization of Serial MR Images for Therapeutic Assessment of Polycystic Kidney Disease in Transgenic Mice

Baowei Fei [1], Chris Flask [1], Hesheng Wang [2], Ai Pi [2], David L. Wilson [2,1], Jonathan Shillingford [3], Noel Murcia [4], Thomas Weimbs [3], Jeffrey L. Duerk [1,2]

[1] Department of Radiology, Case Western Reserve University & University Hospitals of Cleveland, USA
[2] Department of Biomedical Engineering, Case Western Reserve University, Cleveland, OH, USA
[3] Department of Cell Biology, Lerner Research Institute, The Cleveland Clinic, Cleveland, OH
[4] Department of Pediatrics, Case Western Reserve University, Cleveland, OH

***Abstract* — *In vivo* small animal imaging provides a powerful tool for the study of a variety of diseases. Magnetic resonance imaging (MRI) has become an established technology for the assessment of therapies. In this study, we used high-resolution MRI to evaluate polycystic kidney disease (PKD) in transgenic mice. We used a customized mouse coil to acquire serial MR images from both wide-type and transgenic PKD mice immediately prior to, and 2-week and 4-week after therapy. We developed image segmentation, registration and visualization methods for this novel imaging application. We measured the kidney volumes for each mouse to assess the efficacy of the therapy. The segmentation results show that the kidney volumes are consistent, which are 348.7 ± 19.7 mm^3 for wild-type mice and 756.3 ± 44.1 mm^3 for transgenic mice, respectively. The image analysis methods provide a useful tool for this new application.**

Keywords—**Transgenic mice, polycystic kidney disease, image segmentation, registration, visualization, magnetic resonance imaging (MRI)**

I. INTRODUCTION

Autosomal-dominant polycystic kidney disease (ADPKD) is a common genetic disorder characterized by the formation of fluid-filled renal cysts that can eventually lead to renal failure. ADPKD is one of the most common human monogenetic diseases and affects over 600,000 patients in the USA [1-4]. The disease is characterized by excessive proliferation of renal tubular epithelial cells which form fluid-filled cysts that eventually replace most of the normal kidney tissue. Consequently, ADPKD leads to severe enlargement of the kidneys. No clinical treatment is currently available to delay the onset of renal cystogenesis or slow its progression.

In vivo imaging techniques provide a noninvasive tool for monitoring the progression and/or regression of diseases [5,6]. Serial MRI studies can provide high-resolution anatomic structure of the kidneys and thus could be a useful tool for the assessment of various therapies. In this study, we use high-resolution MRI to measure the kidney volumes of transgenic mice with polycystic kidney disease. We have developed image segmentation, registration and visualization methods for this new application that help to quantify and characterize the impact of therapies.

II. MATERIALS AND METHODS

A. Image Acquisitions

During each imaging session, the animals were mounted on a plastic holder and were provided with a continuous supply of 2% isoflurane (EZAnesthesia, Palmer, PA) in oxygen to minimize motion artifacts in the MR images. We acquired MR images from each mouse immediately before treatment (Week 0), and two weeks (Week 2) and four weeks (Week 4) after treatment.

Mouse images were obtained using a Siemens Sonata 1.5 T scanner (Siemens Medical Solutions, Erlangen, Germany). A custom-designed whole-body mouse coil (2-element phased-array, ID = 32 mm) was used to maximize the image SNR for these high-resolution acquisitions. A three-dimensional (3D) True FISP (True Fast Imaging with Steady-State Free Precession) pulse sequence (TR/TE= 10.4/5.2ms) with a slice thickness of 500 um was used to generate high-resolution coronal images (Matrix = 256 x 192, FOV = 67 x 50-mm). The signals were acquired four times to increase the SNR in the reconstructed images. Sufficient slice over-sampling was obtained to minimize the slice aliasing effects in the renal portions of the 3D acquisitions.

B. Image Segmentation, Registration, and Analysis

We used two methods for the segmentation of the mouse kidneys on MR images. In the first method, we used a manual segmentation method. We first selected coronal slices covering the kidneys (Fig. 1). We then placed 8-15 control points along the boundaries of the kidney. The computer program automatically connected the points using spline curves. The points could be edited by the user. In the second approach, we

developed a semiautomatic segmentation method. We averaged the manually segmented boundaries from different mice and used the result as an initial model for automatic segmentation. To segment a new image, we placed a point within the kidney and deformed the model to the renal boundary. We optimized the intensity gradients along the boundary. We used spline curves and optimized the curves from coarse to fine. We computed the kidney volumes after segmentation.

We used the segmented images for registration. We aligned the corresponding kidneys for further quantitative analyses and image visualization. Based on our previous experiences [9-11], we chose normalized mutual information (NMI) as the similarity measure in our registration because it is robust and suitable for multi-modality image registration. We used rigid body transformation (three translations and three angles) and trilinear interpolation. For optimization, we used the downhill simplex method of Nelder and Mead [12]. Optimization of alignment ends either when the maximum number of NMI calculations is reached (typically 500) or the fractional change in NMI is smaller than a tolerance (typically 0.0001). Our very first initial guesses are all zeros for the three displacements and three angles. We use IDL (Interactive Data Language, Research System Inc., Boulder, CO) as the program language.

We used a variety of visualization methods to display the kidneys and their changes over time. We used volume and surface rendering to visually examine the kidney changes after therapy. We displayed registered images using color overlay, i.e., green for the kidney in Week 0 and red for that in Week 2.

C. Evaluation for Segmentation and Registration

We evaluated the consistency of the segmentation methods. Two users performed the segmentation and one repeated the procedure. We compared the kidney volumes as obtained from different segmentation. We used visual inspections to evaluate the registration. We used *RegViz,* a program written in IDL and created in our laboratory for visualizing and analyzing registered image volumes. Color overlay displays were used to evaluate overlap of structures. One image was rendered in gray and the other in the "hot-iron" color scheme available in IDL. To visualize potential differences, it was quite useful to interactively change the contribution of each image using the transparency scale.

III. Results

The segmentation results show that the kidney volumes as measured from different users are very consistent (Fig. 2). The volume difference is less than 5% between the two users. For the same user, the difference is only 2%. The kidney volume of the transgenic mice (756.3±44.1 mm^3) is doubled as compared to wild-type mice (348.7±19.7 mm^3). Our results also indicates that one kidney is always bigger that the other (Fig. 3). Figure 4 shows the kidneys of the transgenic mouse (No. 4) in Week 0, Week 2, and Week 4. The kidney volume decreased two weeks after treatment indicating the effect of the therapy. However, the volume in Week 4 increased 4% as compared to Week 2 but it is still less than Week 0 probably because of the nature growth of the kidney.

IV. Discussion & Conclusion

The image segmentation, registration and visualization methods could provide a useful tool for the new application of *in vivo* assessment of polycystic kidney diseases in transgenic mice. More animal imaging experiments and data analyses are planned in the future. We are integrating the image analysis methods into a single package for this important application.

Acknowledgment

The algorithm developed in this research was supported by the DOD grant DAMD17-02-1-0230 to Baowei Fei . The animal study was supported by a grant from the NIH R01-DK62338 to Thomas Weimbs.

References

[1] V.E.Torres, P.C.Harris, Autosomal dominant polycystic kidney disease. *Nefrologia,* vol. 23 Suppl 1, pp.14-22, 2003.

[2] P.Igarashi, S.Somlo, Genetics and pathogenesis of polycystic kidney disease. *J Am Soc Nephrol.,* vol.13, pp.2384-2398, 2002.

[3] P.D.Wilson, Polycystic kidney disease. *N Engl J Med.,* vol.350, pp. 151-164, 2004.

[4] M.Sutters, G.G.Germino, Autosomal dominant polycystic kidney disease: molecular genetics and pathophysiology. *J Lab Clin Med.* Vol.141, pp. 91-101, 2003.

[5] T.L.Chenevert, C.R.Meyer, B.A.Moffat, et al., Diffusion MRI: a new strategy for assessment of cancer therapeutic efficacy, *Mol Imaging*, vol. 1, pp. 336-343, 2002.

[6] S.K.Lyons, Advances in imaging mouse tumour models in vivo, *J Pathol.*, vol. 205, pp. 194-205, 2005.

[7] N.E.Brown, N.S.Murcia, Delayed cystogenesis and increased ciliogenesis associated with the re-expression of polaris in Tg737 mutant mice. *Kidney Int,* vol. 63, 1220-1229, 2003.

[8] J.Nauta, Y.Ozawa, W.E.Sweeney, J.C.Rutledge, E.D.Avner, Renal and biliary abnormalities in a new murine model of autosomal recessive polycystic kidney disease. *Pediatr Nephrol,* vol. 7, pp. 163-172, 1993.

[9] B.Fei, A.Wheaton, Z.Lee, J.L.Duerk, and D.L.Wilson, Automatic MR volume registration and its evaluation for the pelvis and prostate, *Physics in Medicine and Biology*, vol. 47, pp. 823-838, 2002.

[10] B.Fei, J.L.Duerk, and D.L.Wilson, Automatic 3D Registration for Interventional MRI-Guided Treatment of

Prostate Cancer, *Computer Aided Surgery*, vol. 7, pp. 257-267, 2002.
[11] B.Fei, J.L.Duerk, D.T.Boll, J.S.Lewin, and D.L.Wilson, Slice-to-volume registration and its potential application to interventional MRI-guided radio-frequency thermal ablation of prostate cancer, *IEEE Trans Med Imaging*, vol. 22, pp. 515-525, Apr, 2003.
[12] J.Nelder and R.A.Mead, A simplex method for function minimization, *Computer Journal*, vol. 7, pp. 308-313, 1965.

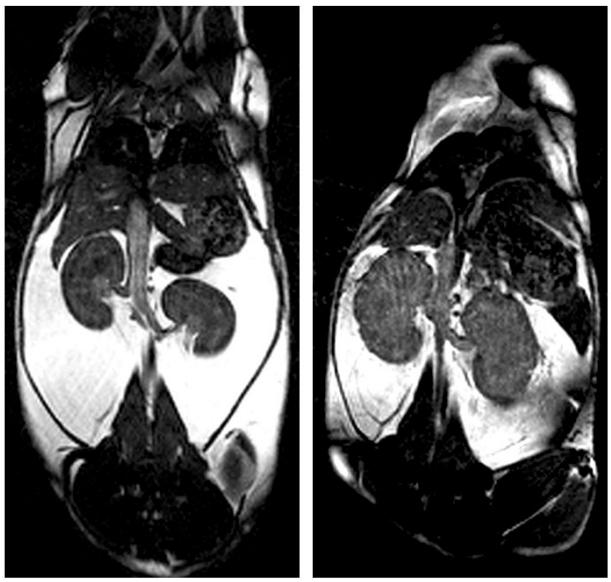

Fig. 1. Kidney MR images from the wild-type (left) and transgenic (right) mice. The transgenic mouse had the polycystic kidney disease.

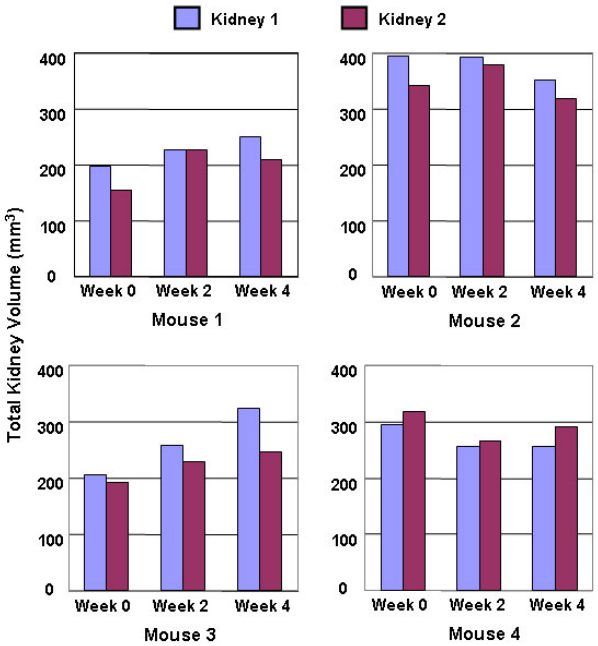

Fig. 3. Volume comparison of two kidneys of mice.

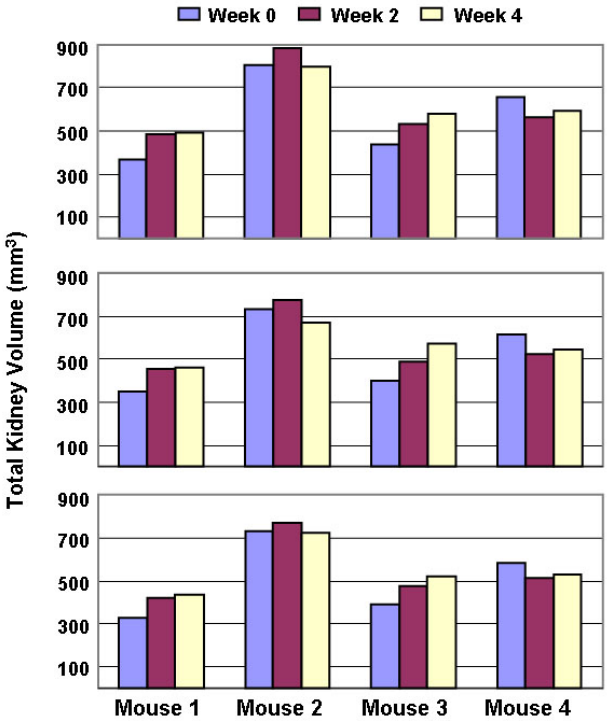

Fig. 2. Mouse kidney volumes. The top is the segmentation results from User A. The middle and bottom are the results from User B as performed at different time. Mouse 1 and 3 are wild-type and Mouse 2 and 4 are transgenic.

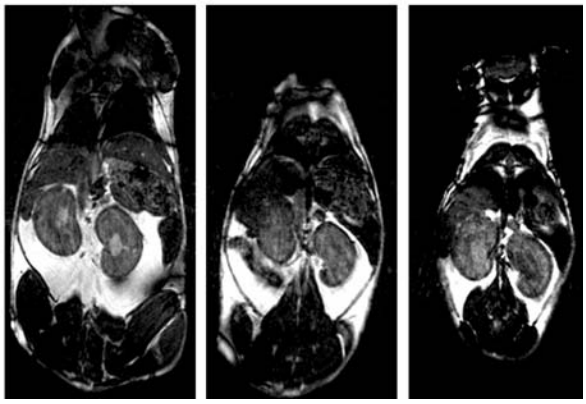

Fig. 4. Serial MR images of mouse kidneys. Images are from the transgenic Mouse 4 as acquired in Week 0 (left), Week 2 (middle) and Week 4 (right).